PREVENTION. CARE. RECOVERY.

Te Kaporeihana Āwhina Hunga Whara

The Diagnosis and Management of Soft Tissue Shoulder Injuries and Related Disorders

BEST PRACTICE EVIDENCE-BASED GUIDELINE

NEW ZEALAND GUIDELINES GROUP

Promoting Effective Health and Disability Services

Statement of intent

Evidence-based best practice guidelines are produced to help health practitioners and consumers make decisions about health care in specific clinical circumstances. Research has shown that if properly developed, communicated and implemented, guidelines can improve care. The advice on soft tissue injuries of the shoulder given in this guideline is based on epidemiological and other research evidence, supplemented where necessary by the consensus opinion of the expert development team based on their own experience.

While guidelines represent a statement of best practice based on the latest available evidence at the time of publishing, they are not intended to replace the health practitioner's judgment in each individual case.

The guideline is endorsed by:

NZ Association of Musculoskeletal Medicine

New Zealand Orthopaedic Association

New Zealand Society of Physiotherapists Inc.

The Royal Australian and New Zealand College of Radiologists – New Zealand

Royal New Zealand College of General Practitioners

Sports Medicine New Zealand Inc

The guideline is supported by:

Arthritis New Zealand

NEW ZEALAND GUIDELINES GROUP
Promoting Effective Health and Disability Services

ACC
PREVENTION. CARE. RECOVERY.
Te Kaporeihana Āwhina Hunga Whara

Contents

Purpose III

About the guideline V

Key Messages XI

Algorithm XII

Summary table: clinical assessment of the shoulder XV

Chapters

Background 1
Initial diagnosis and management 3
Rotator cuff disorders 11
Frozen shoulder 19
Glenohumeral instabilities 25
Acromioclavicular joint disorders 33
Sternoclavicular joint disorders 37
Cultural considerations 39
Implementation 41
Further research 43

Appendices

Appendix A: Evidence and Recommendation Grading System 47
Appendix B: Guideline Methodology 51

Abbreviations 55

Glossary 57

References 59

Purpose

The purpose of the guideline is to provide an evidence-based summary of the diagnosis and management options available for soft tissue shoulder injuries and related disorders to assist health practitioners and consumers to make informed decisions to improve health outcomes.

About the guideline

Introduction

The Accident Compensation Corporation (ACC) commissioned and funded the New Zealand Guidelines Group (NZGG) to develop an explicit evidence-based guideline in response to evidence of variation in practice in the diagnosis and management of soft tissue shoulder injuries.

The NZGG is a not-for-profit organisation established to promote effective health and disability services. NZGG facilitates the development and implementation of guidelines across all areas of health care in New Zealand. Guidelines make a contribution to this aim by sharing the latest international studies and interpreting these in a practical way for adoption in the New Zealand setting.

The development of the guideline was led and managed by the Effective Practice, Informatics and Quality Improvement (EPIQ) Group under the auspices of the NZGG. The EPIQ group is based in the School of Population Health in the Faculty of Medical and Health Sciences at the University of Auckland. The centre is a collaboration of academics, clinicians and other health sector professionals, who undertake training, research and development in evidence-based practice, health informatics and quality improvement for the health and disability sector.

For more information on the NZGG visit www.nzgg.org.nz

Guideline development process

In February of 2003, NZGG convened a multidisciplinary team of stakeholder groups and consumers to develop the guideline chaired by Associate Professor Bruce Arroll, (Dept of General Practice and Primary Health Care, University of Auckland) with Gillian Robb (EPIQ, University of Auckland) as full time project manager. Team members were nominated by stakeholder groups and invited to take part. The team held two major meetings during the year and several shorter meetings to discuss aspects of guideline development.

At the first meeting the Guideline Development Team defined the clinical questions and scope of the guideline. Based on these questions, a systematic search of the literature was undertaken to identify relevant studies. Inclusion and exclusion criteria were applied to select the studies to be used in the guideline. For this guideline, only meta-analyses, systematic reviews and randomised controlled trials were considered for treatment interventions.

Evidence grading system

The grading system used for this guideline involved three stages (refer to Appendix A for further details).

1. Individual studies were critically appraised and assessed for methodological quality using the Generic Appraisal Tool for Epidemiology (GATE) appraisal tools (developed by Professor Rod Jackson, University of Auckland, and available at: www.epiq.co.nz) and assigned a quality rating.

2. Each study was then assigned an evidence level using the Scottish Intercollegiate Guidelines Network (SIGN) grading system, which incorporates the quality assessment with the study type. Level of evidence [4] includes both published expert opinion and the consensus of the Guideline Development Team. The SIGN grading system does not include diagnostic tests, so we have included a separate system for identifying the level of evidence for diagnostic tests. Throughout the guideline, the level of evidence has been included alongside the references, formatted as: reference (level of evidence).

3. The third step involved the development of evidence tables and the consideration of the whole body of evidence ie, all the studies relevant to the issue, and this was used to decide on a recommendation and an appropriate Recommendation Grade. The Guideline Development Team agreed on the recommendations using the 'Considered Judgment' Form. The NZGG Considered Judgment Form and Evidence Tables are available at NZGG's website (www.nzgg.org.nz - click on 'Guidelines', then title of the Guideline, then 'Supporting Materials').

Grades of recommendations

The grades A to I are a measure of the strength of evidence underlying the recommendations and should not be construed as an indication of the relative importance of the recommendations.

In this guideline, Grade C refers to recommendations that were developed from published expert opinion (eg, consensus documents). Expert opinion has only been cited where there was no higher level of evidence.

The good practice points are the recommendations developed by the Guideline Development Team in the absence of higher levels of evidence.

Consultation

A draft guideline was widely circulated to consumer groups, primary health care organisations, professional colleges and organisations, expert reviewers, and other clinicians for peer review, and this was modified where possible, as a result of their feedback. The expert reviewers included:

- Steve Bentley, Specialist, Marinoto Clinic, Dunedin
- Adam Dalgleish, Consultant, Middlemore Hospital, Counties Manukau
- William Taylor, Senior Lecturer, University of Otago
- Lisa Hansen, Private Practice, Hamilton
- Pim Allen, Chief Medical Advisor, Waikato District Health Board

- Chris Milne, Sports Physician, Sports Medicine NZ; NZ Medical Director Northern Region, NZ Academy of Sport
- Mary Magarey, Senior Lecturer, School of Health Sciences, University of South Australia
- Mark Jones, Senior Lecturer, School of Health Sciences, University of South Australia
- Memo Musa, Chief Executive Officer, Whanganui District Health Board
- Steven Lillis, Senior Lecturer, Waikato Clinical School
- Anthony Griffen, Clinical Leader Orthopaedic Department, Wellington Hospital
- Richard Newsham-West, Vice President, Sports Medicine NZ
- Kevin Morris, Corporate Medical Advisor, ACC
- Cindy Farquhar, Postgraduate Professor of Obstetrics and Gynaecology, University of Auckland National Women's Hospital
- Gary Collinson, General Practice, Auckland
- John Grace, President, NZ Chiropractors Association
- Brett Krause, Orthopaedic Surgeon, Hutt Valley District Health Board

Guideline development team

Chair: Bruce Arroll
MBChB, PhD, FRNZCGP, FAFPHM
Associate Professor General Practice, School of Population Health, University of Auckland

Project Manager: Gillian Robb
MPH (Hons), Dip Physiotherapy, Dip Ergonomics
Epidemiology and Biostatistics, School of Population Health, University of Auckland

Asstistant Project Manager: Bridget Kool
RGON, BHSc(Nursing), MPH(Hons)
Epidemiology and Biostatistics, School of Population Health, University of Auckland

Team members

Tim Astley
MBChB, FRACS
Orthopaedic Surgeon; President of the NZ Society of Shoulder and Elbow Surgeons, Auckland

Craig Ball
MBChB, FRACS
Orthopaedic Surgeon; Shoulder and Elbow Specialist, Auckland

Mia Carroll
MHSc, BA, ADN, RGON
Director, NZGG Advisory Board; Course Coordinator, Bachelor of Nursing Programme, Te Puna Whai Ora - School of Nursing and Health Studies, representing a consumer perspective, Te Puke

Ra Durie
MBChB, FACSP, Dip Sports Med (Auckland)
Sports Physician. representing a Maori perspective, Palmerston North

Peter Gendall
MBChB, FRANZCR
Musculoskeletal Radiologist, Auckland

Chris Hanna
FACSP, MBChB (Otago), Dip Sports Med (Auckland)
Sports Physician, Auckland

Rob Kofoed
MBChB, Dip Sports Med (London), Dip Comm Emerg. Med (Auckland), FAMPA
Emergency Medicine Practitioner, Auckland

John Mayhew
BSc, MBChB, FRNZCGP, Dip Sports Med (London), Dip Obst, Dip Occ Med
Occupational and Sports Medicine Doctor, Auckland

Robert Moran
MHSc (Osteo), BSc, BSc (ClinSci)
Osteopath, Private Practice; Lecturer, School of Health and Community Studies, Unitec New Zealand, Auckland

Duncan Reid
MHSc (Hons), PGD (Manip Physio), BSc, Dip Physiotherapy, Dip MT, MNZCP
Acting Head, Division of Rehabilitation and Occupation Studies, Auckland University of Technology

James Watt
MBChB, MRCP (UK), FRNZCGP, FAFMM, Dip MSM, Dip Obst
Musculoskeletal Specialist, Auckland

Declaration of competing interests

None declared

Acknowledgements

The Guideline Development Team would like to thank the members of the EPIQ Group for their advice and guidance during the development of the guideline. Thanks are also due to the NZGG team for their support, and for coordinating production of the guideline.

Updates

The guideline will be reviewed and updated every five years. NZGG will appoint an appropriate person to carry out the review and will seek funding for this process from ACC. A comprehensive literature search will be completed to identify any new evidence. Any changes made to the guideline will be circulated to relevant people and organisations for review and agreement. Agreed changes will be widely circulated to relevant health practitioner individuals and groups.

Key Messages

Initial diagnosis and management

- Refer people with red flags **immediately** for specialist evaluation.
- Refer people with displaced and/or unstable fractures, massive tears of the rotator cuff, severe dislocations and failed attempts at reduction, **urgently** for specialist evaluation.
- If a significant rotator cuff tear is suspected, refer for diagnostic ultrasound.
- If there is a suspected fracture, or a dislocation in a person aged >40 years, arrange an x-ray.

Rotator cuff tendinosis, partial and full thickness tears

- Use NSAIDs with caution. Simple analgesics may be sufficient.
- Use subacromial corticosteroid injection with caution (provides short-term symptomatic relief for people with tendinosis and partial thickness tears, but may suppress healing).
- A referral for a trial of supervised exercise is usually beneficial.
- If a full thickness rotator cuff tear has not improved with non-operative management by 4 – 6 weeks, refer the person to an orthopaedic specialist.
- Refer those with tendinosis and partial thickness tears at 6 months if there is no improvement with non-operative management.

Frozen shoulder

- Typically presentation is pain and significant functional limitation in women aged 40 – 60 years.
- Treat in the painful stage with an intra-articular corticosteroid injection performed by a competent clinician. People with diabetes require blood sugar monitoring for 24 – 48 hours.
- Initiate a gentle home exercise programme when the acute pain has settled.
- Avoid aggressive mobilisation in the painful phase as this is likely to aggravate symptoms.

Glenohumeral instabilities and dislocations

- Attempt reduction of anterior and posterior dislocations, providing there is appropriate expertise and adequate analgesia.
- If reduction is successful, take x-rays in all those with an acute first-time dislocation (to confirm reduction and assess for bony injury) and check neurovascular function.
- Refer to an orthopaedic specialist if there is insufficient expertise, 2 failed reduction attempts, 2 or more traumatic dislocations or multidirectional instability.

Acromioclavicular joint dislocation

- Grade I and II dislocations can be managed with a sling and analgesia. Heavy lifting and contact sports should be avoided for 8 – 12 weeks.
- Grade III dislocations are mostly managed conservatively but more severe dislocations may require surgical management and should be referred early for evaluation.

Sternoclavicular joint dislocation

- Complete dislocation of the sternoclavicular joint (SC) requires urgent referral to an orthopaedic specialist.
- Consider pulmonary or vascular compromise in posterior dislocations.
- X-rays of the SC joint can be difficult to interpret and CT may be preferred.

Algorithm

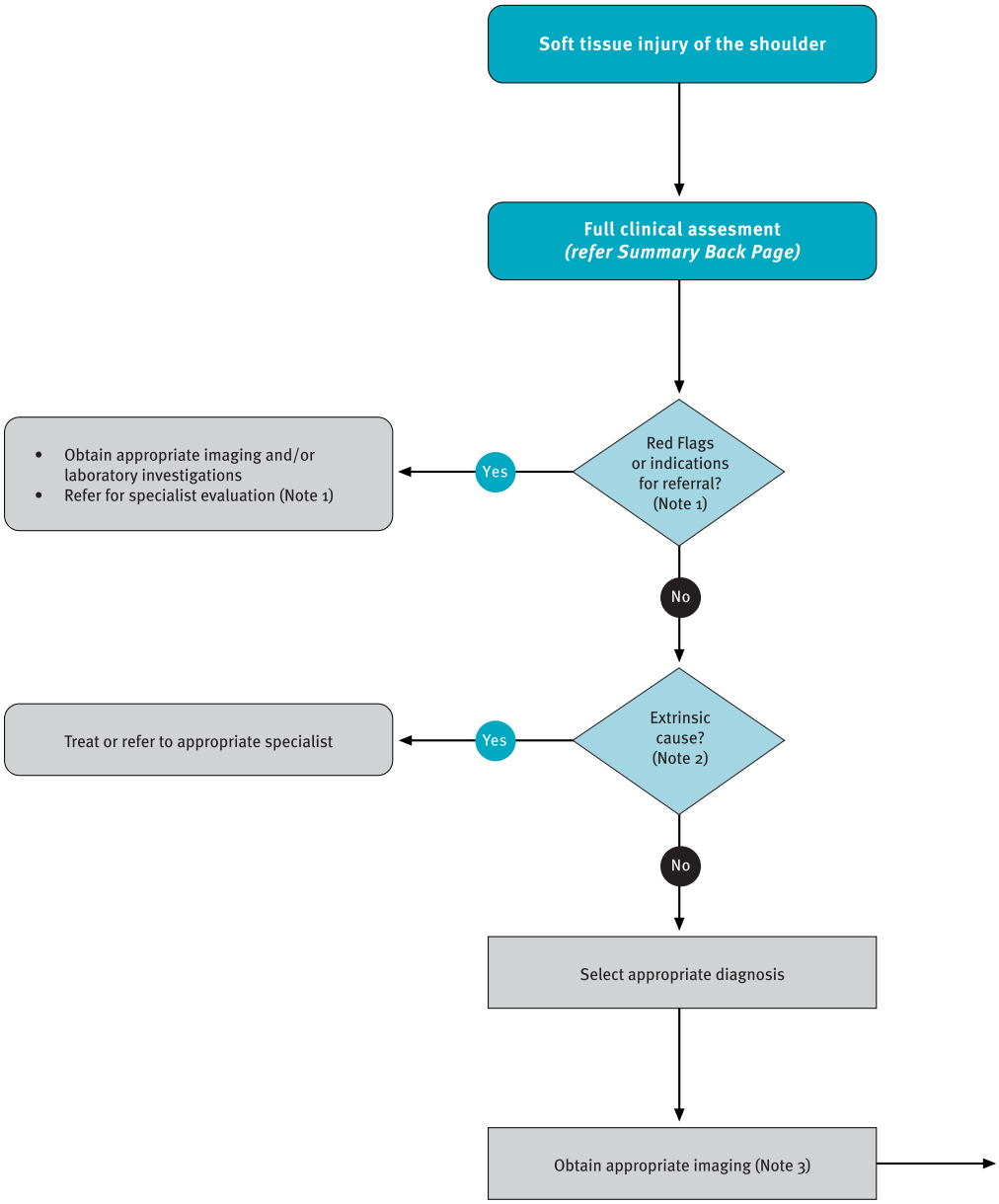

Abbreviations

AC	Acromioclavicular
GH	Glenohumeral
ROM	Range of motion
SC	Sternoclavicular

Rotator Cuff disorders

- Age >35 years
- Upper arm pain/night pain
- Painful arc
- Limited active ROM
- Full passive ROM
- Possible weakness
- +ve impingement signs

Management

Analgesics as required
Activity modification
Trial of rehabilitation
Subacromial steroid injection if appropriate
Review as necessary
Full thickness tear: refer at 4 – 6 weeks if no improvement
Tendinosis/partial thickness tear: refer at 6 months if poor response

Frozen shoulder

- Gradual onset
- Increasing severity of pain
- Global limitation active ROM
- Limited passive ROM
- Possible diabetic

Management

Early painful phase
Intra-articular steroid injection by competent clinician
Gentle home exercise programme
Review 4 – 6 weeks
Consider trial of rehabilitation if poor response or refer to specialist

AC Joint Sprain

- Younger
- Contact sport
- Fall on shoulder
- Pain localised over AC joint
- Tender over AC joint
- Prominence over AC joint
- Cross chest test painful

Management

Sling if necessary
Analgesics as required
ROM exercises as pain permits
Activity modification
Resume activities as tolerated
Review 2 – 3 weeks
If poor response, consider trial of rehabilitation 4 – 6 weeks
Consider referral to specialist if response still not satisfactory

Anterior/recurrent dislocation

- History of trauma
- Pain and muscle spasm
- Empty space below acromion
- Humeral head anterior
- Limited movement
- +/- +ve x-ray confirmation

Management

Attempt reduction if appropriate, using adequate analgesia
Refer urgently if unable to reduce
Provide sling & analgesia
Advise activity modification
If ≥2 recurrent dislocations, refer to specialist
Review 2 – 3 days, then 10 – 14 days
Refer for trial of rehabilitation
Refer to specialist if poor response

Instability disorders

- Age <35 years
- History of dislocation/subluxation
- Overhead work/sports
- Catching pain on activity
- +ve apprehension
- Increased laxity & pain on testing

Management

Refer for specialist evaluation and a definitive diagnosis
Multidirectional instability
Activity modification
Comprehensive rehabilitation programme 3 – 6 months
Review as necessary
Refer to specialist if poor response

Algorithm notes

Note 1: Indices for Referral

Red Flags

- Unexplained deformity or swelling
- Significant weakness not due to pain
- Suspected malignancy
- Fever/chills/malaise
- Significant/unexplained sensory/motor deficit
- Pulmonary or vascular compromise

Indications for urgent referral

- Displaced or unstable fracture
- Failed attempted (x2) reduction of dislocated shoulder
- Massive tear of the rotator cuff (>5 cm)
- Severe dislocation GH, AC or SC joint
- Undiagnosed severe shoulder pain

Indications for early referral

- Full thickness tear of the rotator cuff after 4 – 6 weeks if no improvement
- 2 or more traumatic dislocations
- Recurrent posterior/other instabilities
- Uncertain diagnosis
- Failure to recover within expected timeframe

Note 2: Extrinsic Causes

- Cervical spine disorders
- Nerve disorders
  - Nerve root irritation
  - Nerve compression/entrapment
  - Brachial plexus injuries
  - Neuralgic amyotrophy
- Inflammatory disorders
  - Rheumatoid arthritis
  - Polymyalgia rheumatica
- Complex regional pain syndrome
- Myofascial pain syndrome
- Scapulo-thoracic articulation
- Thoracic and rib injuries
- Visceral disorders

Note 3: Imaging

Modality	Indications
X-rays	• Strong suspicion of fracture • Dislocation in those aged >40 years • Consideration of surgery as a management option (films best ordered by orthopaedic specialist)
Diagnostic ultrasound	• Suspected significant rotator cuff damage

Summary table: clinical assessment of the shoulder

History

Inquiry	Key Features	Consider
Age	>35 years <35 years	Rotator cuff Instability
Mechanism of injury	Fall/direct trauma Fall onto point of shoulder Abduction/external rotation Head away (traction)	Clavicle fracture AC joint Rotator cuff/dislocation Brachial plexus
Pain location/radiation	Above shoulder joint Upper arm/deltoid Anterior upper arm Below elbow (shooting) Night pain	AC joint Rotator cuff Biceps tendonitis Nerve/neck Rotator cuff disorder

Physical Examinaton

Action	Key Features	Consider
Look	Asymmetry/deformity Wasting Bruising Scars	Dislocation/fracture/AC joint dislocation Rotator cuff tear/nerve injury Dislocation/fracture Previous injury/surgery
Feel	SC joint/Clavicle/AC joint Long head biceps Greater tuberosity Spine of scapula	Local tenderness/prominence Local tenderness bicipital groove Local tenderness/?fracture Local tenderness/?fracture
Test Active ROM	Limited active/full passive Painful arc	Rotator cuff disorder (impingement/tear) Rotator cuff disorder
Test Passive ROM	Limited active ***and*** passive Hypermobile Positive apprehension	Frozen shoulder Instability
Test	Weak abduction/wasting deltoid Weak abduction/external rotation Weak internal rotation	Axillary nerve injury (dislocation) Rotator cuff tear Subscapularis/pectoralis major tear
Special tests	There is no evidence any specific test is both valid and reliable for the diagnosis of shoulder injuries	

Neurological Examination

Level	Motor	Sensory	Reflex
C_5	Deltoid/biceps	Upper arm	Biceps
C_6	Wrist extension	Thumb	Brachioradialis
C_7	Wrist flexion/finger extension	Middle finger	Triceps
C_8	Finger grip	Fifth finger	None
T_1	Hand intrinsics	Medial elbow	None

Background

The diagnosis and management of shoulder injuries is one of the most challenging areas of musculoskeletal medicine. Pathologies and their clinical manifestations vary widely from one person to another and pathologies often co-exist, further compounding the diagnostic complexity.

The shoulder joint is the most mobile joint in the body and is therefore inherently unstable. It is vulnerable to injuries from sport, falls and other accidents, as well as to injuries from repetitive loading of the joint from overhead work or sport activities. Changes in the soft tissues occurring with increasing age and genetic factors, such as skeletal design and ligamentous laxity, also predispose the joint to injury and may also influence the outcome of injury.

Differences in definition of injury result in considerable variation in reported incidence and prevalence of shoulder disorders.[1] They have been reported to be the third most common musculoskeletal complaint in the general population and account for about 5% of musculoskeletal consultations to general practitioners.2 The one year period prevalence is reported to range from 20 – 50%, while the lifetime prevalence in the adult population has been reported to be approximately 10%.[1]

New Zealand figures from the ACC indicate that there were 81,000 medical fee claims (59,000 new claims and 22,000 ongoing claims) in 2002 for shoulder injuries, which included soft tissue injuries, fractures and dislocations.[3] The total annual cost for these injuries was around 37 million dollars, with soft tissue injuries accounting for 74%, representing a considerable cost to the public of New Zealand.

Scope

This guideline focuses on the diagnosis and management of injuries related to trauma in the adolescent and adult population. These include rotator cuff disorders, frozen shoulder, glenohumeral (GH) instabilities (acute dislocation and other types of instability), and acromioclavicular (AC) and sternoclavicular (SC) injuries.

The guideline specifically excludes fractures, inflammatory and degenerative arthritic conditions, endocrinological and neurological conditions, hemiplegic shoulder, and chronic pain, including occupational overuse disorders.

The foundation of this document is evidence-based. However, there is a dearth of sound evidence to guide the diagnosis and management of musculoskeletal conditions in general, and shoulder injuries in particular. This guideline has included a distillation of the literature of varying levels of evidence and where there is no evidence we have recorded the expert opinion of the Guideline Development Team as Good Practice Points.

Definitions of shoulder disorders

For the purposes of this guideline, the following terms have been used together with the soft tissue injuries to which they refer.

- **Rotator cuff disorders** include impingement, subacromial bursitis, tendinosis, painful arc syndrome, partial or full thickness and massive tear of the rotator cuff, long head of biceps tendinosis or rupture and calcific tendinitis.
- **Frozen shoulder** is also known as adhesive capsulitis.
- **Instabilities** include acute and recurrent dislocation, and labral injury.
- **AC joint disorders** include dislocation and stress osteolysis.
- **SC joint disorders** include sprain and dislocation.

Figure 1: Definitions of shoulder disorders

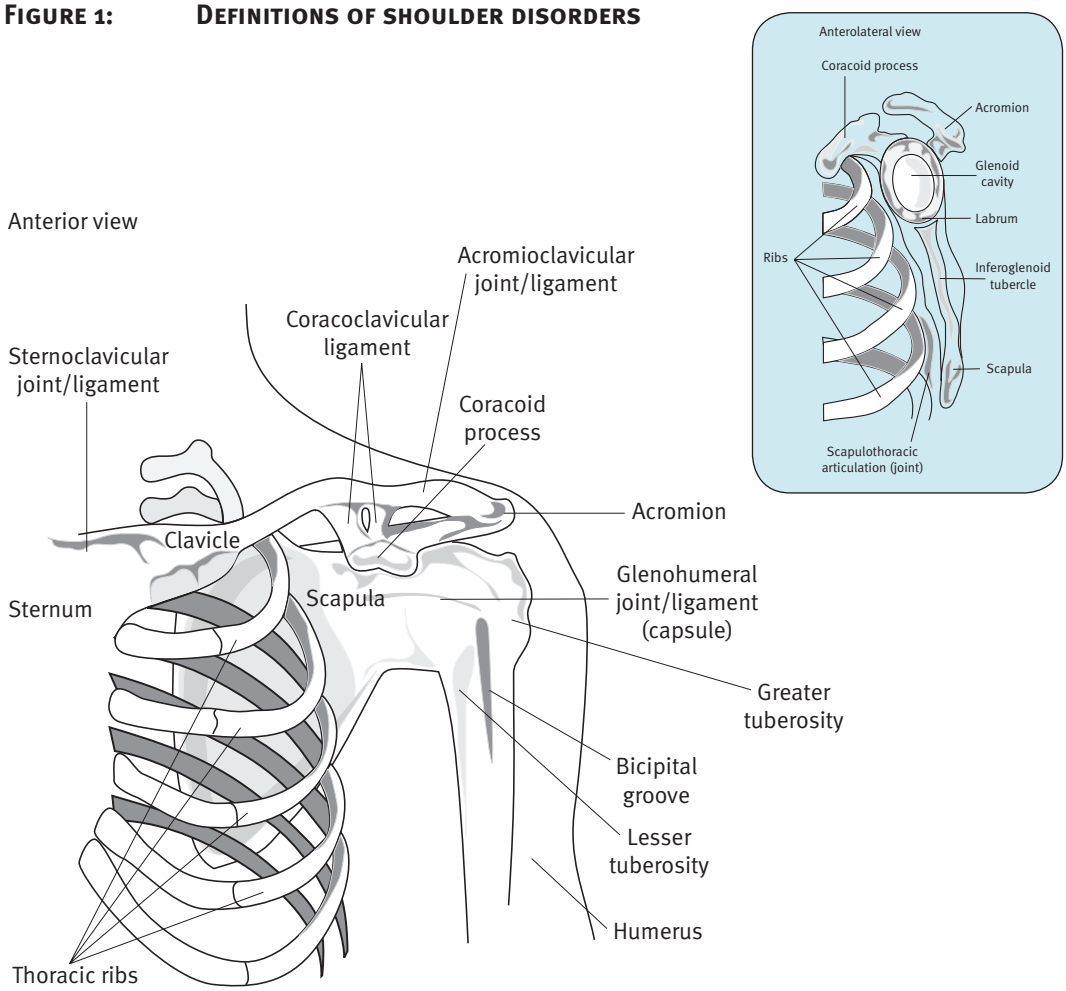

Adapted from Glockner, S. Shoulder Pain: a diagnostic dilemma. *American Family Physician* 1995; 51(7).

Initial diagnosis and management

Overview

- The presence of any red flags indicate an increased likelihood of serious pathology, and the need for immediate referral.
- Significant structural damage requires urgent referral.
- Shoulder pain may be referred, or indicate a systemic disorder.
- Radiology is an important diagnostic tool for shoulder pain, with special views being preferred.
- Diagnostic ultrasound is useful mainly for detecting full thickness rotator cuff tears.
- Magnetic resonance imaging (MRI) is useful for excluding full thickness rotator cuff tears.
- Magnetic resonance arthrography (MR arthrography) is useful for detecting full and partial thickness tears, as well as labral tears.

Recommendation	
A	If a significant rotator cuff tear is suspected, refer for diagnostic ultrasound.
Grades indicate the strength of supporting evidence, rather than the importance of the recommendations – refer to page 49 for grading details.	

Good practice points	
✓	Diagnostic ultrasound should be undertaken by a radiologist with appropriate expertise.
✓	Indications for radiography • Strong suspicion of fracture • Dislocation if aged >40 years or if clinically indicated • Where surgery is being considered as a management option Recommended views • AP glenoid fossa (Grashey) view • Outlet or lateral scapular view • Axial view Plain films are best requested by a specialist, for people referred with shoulder problems that have not responded to non-operative management or where surgery is being considered as a management option.
✓	Refer people with red flags immediately for specialist evaluation.
✓	Refer people with displaced and/or unstable fractures, massive tears of the rotator cuff, severe dislocations, and failed attempts at reduction urgently for specialist evaluation.

Recommended practice based on the professional experience of the Guideline Development Team where there is no other evidence.

History and physical examination

Try to establish an accurate and definitive diagnosis. Check for red flags and other significant structural damage. Screen for extrinsic causes of shoulder pain. Include a neurological examination if indicated.

History		
Inquiry	**Key Features**	**Consider**
Age	>35 years	Rotator cuff
	<35 years	Instability
Mechanism of injury	Fall/direct trauma	Clavicle fracture
	Fall onto point of shoulder	AC joint
	Abduction/external rotation	Rotator cuff/dislocation
	Head away (traction)	Brachial plexus
Pain location/ radiation	Above shoulder joint	AC joint
	Upper arm/deltoid	Rotator cuff
	Anterior upper arm	Biceps tendinitis
	Below elbow (shooting)	Nerve/neck
	Night pain	Rotator cuff disorder

Physical examination		
Action	**Key features**	**Consider**
Look	Asymmetry/deformity	Dislocation/fracture/AC joint dislocation
	Wasting	Rotator cuff tear/nerve injury
	Bruising	Dislocation/fracture
	Scars	Previous injury/surgery
Feel	SC joint/clavicle/AC joint	Local tenderness/prominence
	Long head biceps	Local tenderness bicipital groove
	Greater tuberosity	Local tenderness/?fracture
	Spine of scapula	Local tenderness/?fracture
Test active ROM*	Limited active/full passive	Rotator cuff disorder (impingement/tear)
	Painful arc	Rotator cuff disorder
Test passive ROM*	Limited active and passive	Frozen shoulder
	Hypermobile Positive apprehension	Instability
Test	Weak abduction/wasting deltoid	Axillary nerve injury (dislocation)
	Weak abduction/external rotation	Rotator cuff tear
	Weak internal rotation	Subscapularis/pectoralis major tear
Special tests	There is no evidence that any specific test is both valid and reliable for the diagnosis of shoulder injuries	

*ROM: range of movement

Neurological examination			
	Motor	**Sensory**	**Reflex**
C5	Deltoid/biceps	Upper arm	Biceps
C6	Wrist extension	Thumb	Brachioradialis
C7	Wrist Flexion/finger extension	Middle finger	Triceps
C8	Finger grip	Fifth finger	None
T1	Hand intrinsics	Medial elbow	None

Referral

Indications for immediate referral: Red flags

Red flags are signs or symptoms that alert the clinician to serious pathology and the need for immediate referral to an appropriate specialist. These include:

- unexplained deformity or swelling
- significant weakness not due to pain
- suspected malignancy
- fever/chills/malaise
- significant/unexplained sensory/motor deficit
- pulmonary or vascular compromise.

Indications for urgent referral

- Displaced or unstable fracture
- Failed attempted (x2) reduction of dislocated shoulder
- Massive tear of the rotator cuff (>5 cm)

- Severe dislocation of GH, AC or SC joint
- Undiagnosed severe shoulder pain

Indications for early referral

- Two or more traumatic dislocations
- Recurrent posterior or other instabilities
- Full thickness tear of the rotator cuff and no improvement after 4 – 6 weeks
- Uncertain diagnosis
- Failure to recover within expected timeframe

Extrinsic causes of shoulder pain

The site of pain may not be the source of the problem. Consider the following:

- cervical spine disorders
- nerve disorders
  - nerve root irritation
  - nerve compression/entrapment
  - brachial plexus injuries
  - neuralgic amyotrophy (Parsonage Turner Syndrome)
- inflammatory disorders
  - rheumatoid arthritis
  - polymyalgia rheumatica
- complex regional pain syndrome
- myofascial pain syndrome
- scapulo-thoracic articulation
- thoracic and rib injuries
- visceral disorders.

Provide appropriate treatment or refer to a specialist for further evaluation and management.[4]

Imaging

Routine x-rays and diagnostic ultrasound are the imaging techniques commonly available to primary health care providers. Referral to a specialist is required for other diagnostic imaging procedures commonly used for soft tissue injuries of the shoulder, including MRI and MR arthrography.

X-rays

No validated clinical decision rules were located to guide the use of x-rays in people presenting with an acute shoulder injury to assess bony injury. However, standard radiography is considered an important diagnostic tool in the evaluation of shoulder pain.[4]

Indications for x-ray [4]

- Suspicion of fracture
- Dislocation (for people aged >40 years, or where clinically indicated)

Where surgery is being considered as a management option, x-rays are best requested by the orthopaedic surgeon to ensure appropriate views are obtained.[4]

Recommended views [4]

- AP glenoid fossa (Grashey) view
- Outlet or lateral scapular view
- Axial view

Diagnostic ultrasound

Diagnostic ultrasound is a relatively simple and inexpensive imaging technique and there is good evidence that it is a valid diagnostic tool in the diagnosis of full thickness rotator cuff tears in a secondary care setting.[5][DSR++]

The usefulness of diagnostic ultrasound in detecting rotator cuff tears in a primary care setting has yet to be determined, although its value is well established in a secondary care setting. In applying these results, primary care practitioners should be aware that due to the lower prevalence of rotator cuff tears in the primary care setting, it is possible that diagnostic ultrasound may not be as useful as in a secondary care setting.

The ability of diagnostic ultrasound to rule out rotator cuff disease with a negative test is yet to be determined and there is no conclusive evidence for the validity of diagnostic ultrasound in the diagnosis of partial tears.[5][DSR++]

The effectiveness of diagnostic ultrasound varies depending on both the equipment and operator.[1,4][4] The Guideline Development Team recommended that diagnostic ultrasound should be undertaken by a radiologist with appropriate expertise using equipment with sufficient resolution (a transducer with a minimum frequency of at least 8 MHz).[4]

Indications for diagnostic ultrasound

- Suspected rotator cuff damage where it is important to exclude a significant tear.

Magnetic resonance imaging

MRI and MR arthrography have become important techniques for evaluating shoulder abnormalities.[6]

There is good evidence that MRI can rule out a full thickness rotator cuff tear, but the evidence for MRI in ruling in rotator cuff tears has yet to be established.[5][DSR++] There is insufficient evidence to determine the validity of MRI in the detection of labral tears.

MR arthrography is a more recent technique involving the use of intra-articular contrast. There are a few studies in the literature suggesting that it may be accurate in the detection of full thickness rotator cuff tears and more accurate than diagnostic ultrasound and MRI in detecting partial tears.[5][DSR++]

There is some evidence that MR arthrography is valid for the detection of labral tears.[7-10][D+]

Rotator cuff disorders

Overview

- Rotator cuff disorders are the most common source of shoulder problems.
- Tendinosis (tendinitis) is caused by collagen fibre fatigue and usually develops from repetitive activity at, or above, shoulder height.
- Rotator cuff tears usually occur as a result of trauma, and are rare in the young (age <35 years) but common in older people, in whom the trauma may be minimal, and tears may be asymptomatic.
- Rotator cuff tears need to be distinguished from bicipital tendinosis, calcific tendinitis, and an AC joint problem, although the latter often occurs with a rotator cuff tear. Clinical tests are not that useful, although weakness not due to pain indicates a rotator cuff tear.
- NSAIDs have no demonstrated advantage over simple analgesics but have the potential for significant adverse effects.
- Tendinosis and partial thickness rotator cuff tears may benefit from subacromial steroid injection and supervised exercise, but therapeutic ultrasound is of no benefit. If there is no improvement after 6 months, operative management should be considered.
- Full thickness tears need early repair, if occurring in those who are active and physiologically young, while for others, subacromial steroid injection and supervised exercise may be beneficial.

Recommendation	
B	Prescribe NSAIDs with caution. They provide short-term symptomatic pain relief, but can have serious consequences.
B	Use subacromial corticosteroid injection with caution. It provides short-term symptomatic relief for people with tendinosis and partial thickness tears.
B	Provide a trial of supervised exercise by a recognised treatment provider for people with rotator cuff disorders.
B	Avoid use of therapeutic ultrasound (no additional benefit over and above exercise alone).

Grades indicate the strength of supporting evidence, rather than the importance of the recommendations – refer to page 49 for grading details.

Good practice points	
✓	Simple analgesics provide pain relief with less potential for serious side effects.
✓	Informed consent for subacromial steroid injection should include the risk of infection (very rare), transient red face particularly in women, and sometimes 'post-injection flare of pain'.
✓	Subacromial corticosteroid may be appropriate for full thickness tears as part of long-term management where surgery is not being considered as a treatment option.
✓	If there is no significant improvement in those with a full thickness tear of the rotator cuff after 4 – 6 weeks of non-operative management, refer to an orthopaedic specialist.
✓	Early surgical management for a rotator cuff tear has the most to offer people with otherwise healthy tissue and who are physiologically young and active.
Recommended practice based on the professional experience of the Guideline Development Team where there is no other evidence available	

Background

Rotator cuff disorders are by far the most common source of shoulder problems, ranging from mild strain causing impingement type symptoms, to massive tears with total absence of the cuff and severe loss of function.[11] They can occur in athletes, workers with repetitive overhead activities and the elderly with years of use.[12]

Epidemiology

Rotator cuff tears are relatively rare before the age of 35 years. Partial tears of the rotator cuff are more common than full thickness tears, but the incidence of full thickness tears increases with increasing age and by the age of 70 or 80 years, cuff tears may be present in >50% of people. These tears are usually compatible with normal painless functional activity. Traumatic cuff tears in the older person are commonly associated with dislocation and may also involve the subscapularis.[13]

Diagnosis

Rotator cuff disorders are commonly described as tendinosis, partial thickness tears, full thickness tears and massive tears.

Note: 'Tendinitis' implies a pathology that is not strictly correct. Instead, one should use the term 'tendinosis' which is not an inflammatory disorder.

- Tendinosis describes a process involving fatigue failure of collagen fibres (degeneration) frequently due to aging, microtrauma or vascular compromise.[14]

- Partial thickness tears can occur on the bursal or articular side of the rotator cuff and do not extend through the full thickness of the tendon.[15]

- Full thickness tears extend through the full thickness of the tendon.[13]

- Massive tears have been defined as tears >5 cm, but others prefer to classify these as tears involving 2 or more tendons (usually supraspinatus and infraspinatus, but also supraspinatus and subscapularis).[16]

AC joint problems are often associated with rotator cuff tears. Together with bicipital tendinosis and calcific tendinitis, these injuries should be considered part of the differential diagnosis.

History

Tendinosis usually develops as a consequence of repetitive activity, usually at shoulder height or above.

Rotator cuff partial or full thickness tears are usually a consequence of trauma, but in the older age group may happen with minimal trauma and are frequently asymptomatic.

The pain is typically felt around the lateral deltoid or the point of the shoulder. There may be referral to the deltoid insertion and sometimes to the elbow.[17]

Activity-related and night pain are characteristic but non-specific. A painful arc is the classic clinical manifestation of impingement.[18]

Paradoxically, tendinosis and associated impingement, or a small tear, in a young person, may manifest symptomatically greater than a larger tear in an older person. A full tear may be pain-free.

In the case of a major tear, people often report that 'something serious' has happened, or that they have 'torn something'.[4]

Physical examination

Various clinical tests for rotator cuff disorders have been described.[19]

No single clinical test or combination of tests is both reliable and valid for the diagnosis of a partial or complete rotator cuff tear.[5][DSR++] A clinical examination carried out by a specialised clinician may be able to rule out a rotator cuff tear, but is less effective at detecting tears.[5][DSR++]

Weakness is the primary sign of loss of integrity of the rotator cuff. Weakness from pain inhibition can be misleading and subacromial injection of local anaesthetic may clarify the cause of the weakness.[13]

Investigations

In New Zealand, diagnostic ultrasound is the imaging technique most commonly used and is a valid diagnostic test for full thickness rotator cuff tears.

Non-operative management

Due to lack of agreement in defining shoulder disorders, poor quality of studies, and heterogeneity of studies with respect to participants, interventions, and outcomes, there is little evidence to support or refute the efficacy of common interventions for shoulder disorders in general,[20,21][1++] and rotator cuff disorders in particular.[12][1++]

The guideline team were in agreement however that the following description of the management for each subgroup is appropriate.

Tendinosis/partial tears

- **Analgesia:** Anti-inflammatory drugs provide short-term pain relief in acute shoulder pain.[22][1+] However, the advantage may be no more than the analgesic effect, and any benefit must be balanced against possible adverse effects, including gastrointestinal bleeding, alterations in renal and platelet function, hepatitis and bronchospasm.[22,23] Simple analgesics such as paracetamol, may provide adequate analgesia and have less potential for serious consequences.

- **Subacromial steroid injection:** While there is controversy about the benefits of subacromial steroid injection, there is some evidence that it provides short-term symptomatic relief for people with shoulder pain including rotator cuff disorders. [20][1++] [21][1++] [24][1++] [25][1+] There was insufficient evidence to determine the benefits of steroid injection for people with confirmed partial or full thickness rotator cuff tears.[12][1++] The relative benefits of corticosteroid injection and physiotherapy remain unclear. A Cochrane review based on 4 trials of limited quality found corticosteroids to be superior to physiotherapy.[20] In a recent high-quality pragmatic trial of physiotherapy compared with corticosteroid injection for people with new episodes of shoulder pain, no differences were found between groups.[26][1+]

  No reported adverse effects for subacromial injection for rotator cuff disorders were located, although facial flushing was reported following the use of intra-articular corticosteroid injection in people with adhesive capsulitis (RR=9.0, 95% CI 1.18 – 68.74).[24,27] Other possible adverse effects include post-injection flare, thought to be caused by preservatives in the injectable suspension. This is usually limited to 24 – 36 hours and can be relieved by the application of ice packs.28 Infection is rare and should be avoided by use of sterile technique although clinicians should watch for any significant increase in joint pain following joint injection. Tendon rupture can be prevented by avoiding direct injection into the tendon. Hyperglycaemia is possible in patients with diabetes.[28] The long-term harms have not yet been established. Subacromial steroid injection should therefore be used with caution. The Guideline Development Team also felt it was important that practitioners document informed consent for this procedure.

- **Rehabilitation:** There is some evidence that supervised exercise is beneficial, and good evidence that ultrasound is of no additional benefit over and above exercise alone.[20] [1++]

- **Referral:** Referral to an orthopaedic specialist is appropriate if there is failure to improve at 6 months or longer, or at the person's request.

Full thickness rotator cuff tear

- **Analgesia**: Anti-inflammatory drugs provide short-term pain relief in acute shoulder pain.[22][1+] However, the advantage may be no more than the analgesic effect, which can be achieved with simple analgesics with less potential for serious consequences.

- **Subacromial steroid injection:** There is insufficient evidence to determine the benefits or harms in full thickness rotator cuff tears.[12][1++] However, the Guideline Development Team were in agreement that for people with full thickness tears, steroid injection is not appropriate if surgery may be considered as a future treatment option, although it may be appropriate as part of long-term management where surgery is not being considered.

- **Rehabilitation:** A supervised exercise programme may be of limited benefit when the acute symptoms have settled.[4]

- **Referral:** Early referral (within 4 – 6 weeks) to an orthopaedic surgeon is indicated in active people who are 'physiologically young' with significant structural damage due to reasonably severe trauma. In older, more sedentary people, where cuff failure is largely due to attrition, with tendon atrophy or retraction on imaging, operative management may not be appropriate. However, where there is doubt about surgery as a treatment option, it is better to refer people for an orthopaedic evaluation.

Massive tears

There is no agreement on the definition of a massive tear. It is generally accepted that a tear >5 cm in diameter would be classified as a massive tear. However some prefer to classify a massive tear as one involving two or more tendons.[16]

Massive tears usually involve all of supraspinatus and infraspinatus, or all of supraspinatus and subscapularis. These tears are distinct from a smaller full thickness tear because of the greater potential and rapidity of retraction and atrophy resulting in less favourable outcomes if repair is delayed.

People with massive tears should be referred immediately to an orthopaedic specialist.[4]

Operative management of rotator cuff tears

There is insufficient evidence regarding the benefit of surgical versus non-operative management of rotator cuff tears.[12][1++] However, there is a consensus that early surgical

management for a massive tear has the most to offer people with otherwise healthy tissue and who are 'physiologically young' and active.[4]

When evaluating the benefit of surgery, consider the functional demands of the person and the likelihood of achieving treatment goals.[16]

Related disorders

Biceps tendon disorders

Although long head of biceps tendinosis may occur in relative isolation, it is part of the spectrum of pathological processes of rotator cuff disorder. It is more common with increasing age, and should be managed in the same way as rotator cuff tendinosis.

Isolated bicipital tendinitis is not common. Refer to an orthopaedic specialist where instability (subluxation or dislocation) of the biceps tendon is suspected.

Rupture of the long head of biceps usually occurs in a degenerative tendon and is therefore more common with increasing age.[29] There is almost no indication for operative repair of the acutely ruptured long head of biceps and the symptoms usually eventually subside spontaneously. Management is symptomatic and should include an explanation of the nature of the problem.

Calcific tendinitis

This is an enigmatic condition considered to be a form of dystrophic calcification. It occurs spontaneously and is usually self-limiting, although the natural course is variable.[30]

The usual site of calcific tendinitis is in the supraspinatus tendon, affecting mainly women aged 40 – 50 years. The reported incidence varies from 2.5 – 20% in people with asymptomatic shoulders and up to 54% in people with shoulder disorders.[31]

Clinical symptoms vary, and many cases resolve spontaneously.[31] An acute calcific tendinitis is one of the causes of very severe pain (a 'chemical boil'). At the other end of the spectrum, deposits may reside quite asymptomatically and are often diagnosed as an incidental finding at the time of injury.

Plain x-ray or ultrasound are the diagnostic tests of choice.[4]

Therapeutic ultrasound has been demonstrated to offer a benefit in terms of pain reduction and improved quality of life at the end of treatment. However, the benefit was not maintained at 9 months and there was insufficient information to determine how long the benefit lasted. Radiological changes (improvement and resolution) were significant both at the end of treatment and at the 9-month follow-up.[32][1+]

Extracorporeal shock wave therapy (ESWT) has been used for the treatment of chronic calcific tendinitis since the early 1990s.[33] For people with failed non-operative management,

ESWT may offer an alternative to surgery for calcific tendinitis. There is weak evidence of benefit but more high quality trials are needed to determine the effectiveness of this treatment modality.[30][1+] [34-36][1-]

People with severe pain and dysfunction may require urgent referral to an orthopaedic specialist; otherwise referral is appropriate when non-operative treatment has failed, or at the person's request.

Isolated muscle tears

Isolated tears are rare, but occur most commonly in the subscapularis and pectoralis major. Both require immediate referral for orthopaedic evaluation.

Subscapularis

Isolated tears of the subscapularis muscle are frequently missed. These injuries are typically due to a traumatic event involving either a dislocation of the shoulder, or a forceful hyperextension or violent external rotation of the adducted arm.[37 38]

Weakness of internal rotation, excessive external rotation and a positive 'lift-off' test (inability to lift the internally rotated arm away from the small of the back) are indicative of a tear of the subscapularis tendon.[37]

Pectoralis major

Rupture of pectoralis major is rare. It occurs most frequently in active younger men due to work (manual labour) or sport (weight lifting) activities. It has also been reported in an elderly population where it is most likely to have occurred during patient transfers.[39]

Initially swelling may make the diagnosis difficult, although people may report an audible snap or a sensation of tearing. Examination should be repeated when the swelling and haematoma resolve. An abnormal contour of the anterior axillary fold and weakness in the muscle are indicative of a tear of the pectoralis major.

Frozen shoulder

Overview

- Frozen shoulder (Adhesive capsulitis) is frequently poorly diagnosed and managed.
- It is characterised by gradual and spontaneous onset of pain and global restriction of movement of the GH joint, with pain lasting 2 – 3 months, stiffness lasting a further 3 – 12 months and then a gradual return of function over the next 6 – 12 months.
- Diagnosis is clinical, and investigations are not usually necessary unless arthritis is suspected.
- Initial management involves provision of moderately strong analgesia, and intra-articular (glenohumeral) steroid, which may be technically difficult.
- Exercise will exacerbate the pain in the early phase, but is of benefit once the acute pain has settled.
- Other treatment options that may be of benefit include laser therapy, and exercise plus acupuncture.
- Frozen shoulder occurs more frequently in those with diabetes, especially those with Type 1 Diabetes (IDDM). Transient hyperglycaemia (24 – 48 hours) may develop following intra-articular steroid injection and therefore monitoring and possibly treatment are required.

Recommendation	
B	Actively consider intra-articular corticosteroid injection performed by an experienced clinician, in the painful phase of a frozen shoulder.
B	If required, offer supervised exercise by a recognised treatment provider to improve range of movement after the acute pain has settled.

Grades indicate the strength of supporting evidence, rather than the importance of the recommendations – refer to page 49 for grading details.

Good practice points	
✓	Informed consent for an intra-articular steroid injection should include likelihood of pain, the risk of infection (very rare), transient red face particularly in women, and sometimes 'post-injection flare of pain'.
✓	People with diabetes should have their blood sugar levels monitored following corticosteroid injection and there should be appropriate contingency plans in place if hyperglycaemia occurs.
✓	Avoid vigorous stretching in the early painful phase of a frozen shoulder as it will exacerbate pain.
✓	It is most important that people with a frozen shoulder understand the time it takes for this condition to resolve.
Recommended practice based on the professional experience of the Guideline Development Team where there is no other evidence available	

Background

Frozen shoulder is often poorly diagnosed and managed. This is partially due to a lack of agreement about definitions and classification of this disorder, confusing terminology and difficulty differentiating it from other conditions.[40]

The true frozen shoulder (primary or idiopathic frozen shoulder) is characterised by an unknown aetiology, spontaneous and gradual onset of pain and a global restriction of movement in the GH joint due to contracture and loss of compliance of the capsule.[40,41]

While the aetiology is typically unknown, there can be a history of minor trauma and occasional significant injury.

Epidemiology

An accurate incidence of frozen shoulder in a general population has yet to be determined.[40] It is more common in women than men, and typically presents between the ages of 40 and 60 years. Involvement of the contralateral shoulder occurs in up to 17% of cases, typically sequentially rather than at the same time. Same-side recurrences are rare.[42]

The incidence of frozen shoulder is higher in people with diabetes (10 – 20%) and even higher in people with diabetes who are insulin dependent (35%).[40] It occurs at a younger age in people with diabetes, is usually less painful, and does not respond as well to treatment.[43] Both shoulders are often affected and residual pain and stiffness is more common.[42]

Diagnosis

The diagnosis of frozen shoulder is based on the medical history and clinical examination and has been described as a 'clinical diagnosis of exclusion'.[44][4] The single alerting feature is restriction of movement in all directions ('global restriction').

Phases

The clinical presentation of a primary frozen shoulder is classically described as involving three phases: painful, stiff and resolving.[40]

Painful

There is an initial painful phase extending over 2 – 3 months characterised by the gradual onset of aching pain which can become severe, and is worse at night with disturbed sleep. During this active inflammatory stage, the shoulder is painful at rest and on movement, and the range of motion becomes restricted rapidly. It is during this phase that an injection of intra-articular corticosteroid into the GH joint is most likely to be effective.

Stiff

In this phase, lasting usually from 3 – 12 months, stiffness is the predominant feature. The shoulder is usually painful when attempting to move it beyond the restricted range, but movement within the available range is comfortable, and there is no pain at rest. The shoulder may still be painful to lie on, but the constant aching night pain has subsided.

Resolving

The final 'resolution' phase is characterised by a gradual gain in range of movement with less discomfort. This may take a further 6 – 12 months. In many cases, there is residual mild restriction of the range of movement at the shoulder joint, although people do not report functional limitation.[45]

History and physical examination

The key clinical difference between frozen shoulder and rotator cuff impingement or tear is stiffness (limitation of passive range). In the initial stages when the stiffness is not necessarily especially evident, clinical diagnosis can be difficult.

The pain characteristics, while not specific, are nevertheless typical. The pain can be severe especially at night. It is felt in the same distribution as rotator cuff disorders but can radiate down the arm, even below the elbow. It can be associated with 'vague neurological symptoms' which may be confusing. Sudden unguarded movements will produce a sharp severe pain in the shoulder that will 'stop the person in their tracks'.

Examination features include tenderness over the anterior capsule. Global limitation of movement is present, but within the comfortable range there is seldom significant discomfort on resisted movements and there is no weakness.

There is substantial functional limitation and people typically report problems with activities of daily living such as dressing and reaching.[46][4]

Investigations

Imaging studies are not routinely required for the diagnosis of idiopathic frozen shoulder unless the history and physical examination suggest a need for additional investigation to rule out other pathologies (arthritis).

X-rays and ultrasound for frozen shoulder are usually normal. Alterations in the normal joint space on x-ray suggest arthritis.[42]

Blood tests are not usually performed.

Management

Pain associated with a frozen shoulder can be severe and disabling. A detailed explanation of the nature and natural history of the condition is important at the outset so that people do not develop unrealistic expectations.

Moderately strong analgesics are required, but seldom control the night pain adequately.

There is good evidence that intra-articular corticosteroid injection has a therapeutic effect in the early management of frozen shoulder compared with placebo[24][1++] or physiotherapy.[47][1+] Potential adverse effects should be discussed when obtaining informed consent (see Chapter 3: Rotator cuff disorders: Tendinosis/partial tears).

The therapeutic effect is due to suppression of collageneogenesis (fibrosis). The injection must be intra-articular (glenohumeral). Refer the patient unless it can be done with skill. Fluoroscopic guidance should not ordinarily be necessary, but can be useful especially in obese patients. Meticulous sterile technique is necessary, although infection is rare.

Exercise in the acutely painful phase of a frozen shoulder will exacerbate the pain and is more appropriately initiated as the acute pain settles. When this happens, a simple home programme of gentle exercise may be initiated, although a supervised exercise programme has been found to lead to a faster improvement in the range of movement.[47][1+]

Laser therapy may be beneficial in the treatment of frozen shoulder.[20][1++] There is some evidence that exercise and acupuncture, compared with exercise alone, may lead to better outcomes.[48][1+]

Mobilisation plus exercise was not found to be more effective than exercise alone.[20][1++]

There is no evidence that hydrodilation (joint distension with sterile saline solution) is effective.[21][1++]

The optimal timing of the various treatment options is yet to be determined, although aggressive mobilisation should be avoided during the severely painful phase as this is likely to aggravate symptoms.[42]

Corticosteroid injection may increase blood sugar levels for 24 – 48 hours after the injection. For people with diabetes and frozen shoulder, monitoring of blood sugar is recommended, with contingency plans for elevated blood sugar levels.[43] Generally, frozen shoulder in people with diabetes is more difficult to treat compared to those without diabetes, with a lower rate of spontaneous resolution.

Glenohumeral instabilities

Overview

Acute, first-time dislocation

- This usually occurs as a result of trauma, although the mechanism of injury may not be recalled.
- Neurovascular damage is common, but often missed.
- The diagnostic value of radiology is not clear.
- Any method of reduction can be used by an appropriately skilled practitioner, with relaxation being essential and analgesia provided as required. Reduction may cause further damage (bony, neural, vascular), particularly in older people, and **excessive force must be avoided**.
- Following reduction, clinical evaluation (movement, neurovascular function) and x-rays are required.
- Surgical repair should be considered in young people engaged in demanding physical activities, while for others, early mobility reduces subsequent stiffness, and rehabilitation may reduce recurrence.

Recurrent dislocation

- Manage as for an acute dislocation.
- Surgical intervention should be considered after the second dislocation.

Instability

- Includes anterior, posterior and multidirectional instability, as well as labral injuries.
- Surgery may be an option and orthopaedic evaluation is required.

Recommendation	
A	Young adults engaged in demanding physical activities, with a first traumatic shoulder dislocation should be referred for orthopaedic evaluation.

Grades indicate the strength of supporting evidence, rather than the importance of the recommendations – refer to page 49 for grading details.

Good practice points

Investigations

✓	Pre-reduction x-ray is recommended in people aged >40 years. Post-reduction x-ray is recommended for all people with an acute first time dislocation to confirm the reduction and assess for bony injury. X-ray is required for all people with a failed attempt at reduction. X-ray is recommended for those with recurrent dislocation where surgical stabilisation may be a management option.

Acute management

✓	Only clinicians with appropriate expertise should reduce anterior or posterior dislocations. Relaxation is critical for successful reduction. Ensure adequate analgesia is given, if required, before attempting reduction. Attempt slow steady traction for at least 30 seconds. Avoid excessive force while attempting to reduce a dislocated shoulder. Urgent referral to an orthopaedic specialist is required when reduction is unsuccessful after two attempts.

Post-reduction management: non-operative

✓	In people with a primary dislocation for whom non-operative management is appropriate, apply a sling, provide analgesia and refer for a supervised exercise programme. Following dislocation, people should not return to sport for at least 6 weeks, or when they have achieved near normal muscle strength.

Recurrent dislocation

✓	People with recurrent dislocation (>2) should be referred to an orthopaedic specialist to evaluate the need for surgical stabilisation.

Recommended practice based on the professional experience of the Guideline Development Team where there is no other evidence available

Background

Numerous classifications of clinical instability in the shoulder have been published and used, but none have become universally accepted. Furthermore, there is confusion over definitions. A comprehensive classification is therefore not proposed, but terms and definitions, which by common usage are generally understood, will be used.

- **Laxity** is the measured translation (linear displacement) of one articular surface in relation to the other. (Laxity is not a pathological state unless it is qualified as such).

Instability is the symptomatic manifestation of pathological movement of one joint surface in relation to the other. The two are not synonymous and it is for example possible to have a 'very lax joint' without instability and vice versa.[49]

Acute anterior dislocation

Acute anterior dislocation is also known as 'acute primary anterior dislocation' and 'first time dislocation'.

Epidemiology

The classic pathology is the Bankart lesion (the labrum is detached from the rim and the capsule is stripped from the anterior glenoid neck) which occurs in about 85 – 90% of all anterior dislocations.[50] The younger the person, the higher the chance of a recurrent shoulder dislocation. It has been reported that people aged <20 years have a 90% chance of recurrence, while people aged >40 years have a 10% chance of recurrence.[51]

Traumatic dislocation is relatively common in the 6th decade of life.[52] In the older person with an acute dislocation, capsular tears are more likely than labral tears, and concomitant rotator cuff tears should be considered a strong possibility.[50]

Associated pathologies

A Hill-Sachs lesion is a compression fracture of the humeral head, which occurs as the head of the humerus encounters the sharp edge of the glenoid labrum, producing an impaction posterosuperiorly in the humeral head.[53]

Axillary nerve damage associated with an anterior dislocation is common but frequently not diagnosed. The reported incidence of axillary nerve injury after dislocation ranges from 5 – 54% and is more common in people aged >50 years.[54]

In older people with dislocation, associated rotator cuff tears are common.[53] Vascular injuries are rare but are also more likely in older people with fragile blood vessels. Urgent referral to a vascular surgeon is required for evaluation and management.[55]

Clinicians should be aware that fracture, nerve and vascular injuries can also occur at the time of reduction of the dislocation if attempts at reduction are too aggressive.[53,56]

Diagnosis

History & physical examination

- Dislocations occur as a result of varying degrees of trauma depending on the underlying laxity. People with shoulder injuries may not remember the mechanism of injury but it typically involves a fall with the arm externally rotated and abducted.[57]

- The classic attitude of the arm varies, but usually there is significant pain and loss of the normal contour (the empty socket).

- It is important to assess neurovascular function, especially the axillary nerve.

Investigations

- The role of pre- and post-reduction x-rays has been questioned.[58-61] As yet there is insufficient evidence to determine the necessity of pre-reduction or post-reduction radiography in the management of acute shoulder dislocation.

- The Guideline Development Team recommends the following investigations.

  – Pre-reduction x-rays are indicated for people with a first time dislocation who are aged >40 years.[4]

  – Post-reduction x-ray is recommended for all people with an acute first-time dislocation to confirm the reduction and assess for bony injury.[4]

  – X-rays are required for all people with a failed attempt at reduction.[4]

  – X ray is recommended for people with recurrent dislocation where surgery is being considered as a management option.[4]

Management

Attempts at reduction should be carried out as soon as is practically possible, and should be painless, effective and not cause further injury.[62]

Use of medication

In some cases reduction can be achieved without the need for analgesia. The key is muscle relaxation. A calm and reassuring manner is of great value! If 'coaching' does not work in achieving satisfactory relaxation of the person and shoulder muscles, medication should be considered.63 Inadequate relaxation and disimpaction may result in a fracture.

Analgesia or anaesthesia may be considered depending on facilities and the skills of the clinician. There is weak evidence that intra-articular lidocaine (IAL) for the reduction of

shoulder dislocation can be as effective as IV sedation and reduces time in the emergency department.[64-65][1-] [66][1+] IAL is not widely used in the New Zealand setting and its use is not recommended by the Guideline Development Team as a high level of expertise is required to administer an intra-articular injection effectively.

Choice of reduction technique

There are numerous techniques described for reducing a dislocated shoulder, all of which involve traction and disimpaction. There is no evidence that any one method of reduction is more effective than any other. However there was agreement by the Guideline Development Team that slow steady traction for at least 30 seconds is important. This can be achieved with the arm hanging over a table or a bed.[4]

There are risks associated with reducing a dislocated shoulder, particularly in the older osteoporotic person, including fracture, and nerve and vascular damage. Reduction should therefore only be carried out by a person with appropriate knowledge, skill and experience.[56] **Avoid excessive force.**

Where attempts at reduction are not successful (a maximum of 2 attempts) people should be referred urgently to an orthopaedic surgeon.[4]

Post-reduction management

- Check reduction
- Check neurovascular function
- Confirm position with x-ray

While controversial, there is no good evidence that immobilisation will reduce the incidence of recurrence. It has recently been suggested that the traditional position of internal rotation used with the application of a sling following an acute dislocation may contribute to the rate of recurrent dislocation by allowing the labrum to displace. Placing the arm in external rotation provides a greater contact force between the glenoid labrum and the glenoid. A preliminary small randomised trial found that immobilisation in external rotation was effective in preventing recurrent dislocation after 15 months.[67] Further trials are necessary to provide conclusive evidence.

Conventional management following dislocation includes sling, analgesics and a supervised exercise programme. Post-reduction ultrasound may be indicated where there is suspicion of a rotator cuff tear, which is commonly associated with dislocation in older age people.

Following dislocation, return to sport is not advised for at least 6 weeks until normal muscle strength is achieved.[4]

Operative versus non-operative treatment of first-time dislocations

The management of acute first time dislocation is one of the most controversial areas in the field of shoulder instability.68

A recent Cochrane review found that there is limited evidence to support primary surgery for young adults, primarily male, engaged in demanding physical activities, who had sustained a first traumatic shoulder dislocation.[69][1++]

Non-operative management is more appropriate for the older person where recurrent dislocation is less likely, but stiffness, more likely.[70][4] The emphasis for these people is on early mobility, and the strengthening aspect of the rehabilitation programme should be tailored to the functional needs of the individual.[70][4]

Recurrent anterior dislocation

After an initial dislocation, it has been reported that recurrent dislocation occurs in 94% of those aged 11 – 20 years, 79% of those aged 20 – 30 years and 50% of those aged 30 – 40 years. Most redislocations occur within the first 2 years following the initial dislocation.[50]

Age has been found to be one of the most reliable predictors of recurrent dislocation.[71] The extent of the pathology that occurred at the time of injury may also play a role.[72]

Recent studies have suggested that the traditional position of internal rotation and adduction may also contribute to increased rates of recurrent dislocation.[73-75]

Management is similar to that of a primary dislocation, although there is less need for radiography. Refer to an orthopaedic specialist after the second dislocation.

Posterior dislocation

Acute traumatic posterior dislocation

Posterior dislocations represent <5% of all shoulder dislocations and are frequently misdiagnosed radiologically. They can occur from a fall on the outstretched arm, direct trauma to the anterior shoulder, or as a result of seizures or electric shock due to indirect muscle forces.[76] Management in the primary care setting is appropriate where the clinician has the necessary experience and expertise, according to the same principles as for an acute anterior dislocation. Recurrence is rare.

Recurrent posterior instability (including habitual instability)

While anterior instability is the most common presentation of instability, posterior instability can also occur and is more often bidirectional (posterior and inferior instability) or multidirectional rather than being unidirectional. It is usually the result of trauma although a traumatic posterior instability can occur in individuals with generalised ligamentous laxity.[77]

Symptoms usually occur with the arm in a forward flexed, adducted and internally rotated position (eg, rowing, the pull through phase of swimming strokes, and the follow through phase of throwing). The reduction is the symptomatic complaint. Clinically, the posterior stress test is positive and there may be posterior joint line tenderness.[77]

Some people can voluntarily slide their shoulder posteriorly and jump it back. The pathology is a complex relationship between laxity and 'abnormal muscle activity'. Refer for specialist assessment.

Multidirectional instability

Multidirectional instability is frequently over-diagnosed. It is not well understood but is essentially a global laxity of the shoulder joint which allows pathological movement in several directions. The term 'multidirectional instability' was coined by Dr Charles Neer, to distinguish this from 'unidirectional instabilities'.[78,79]

Diagnosis, management and investigation should be done by an orthopaedic specialist although there is much greater indication for non-operative management than, for example, in recurrent anterior shoulder dislocations.

For people with multidirectional instability, a comprehensive rehabilitation programme focusing on strengthening the scapular stabilisers and rotator cuff muscles may improve function. Where such a programme fails to improve function by six months, surgical intervention may be considered.

Other instabilities

Included under this heading are labral injuries, including the SLAP lesion (detachment of the superior labrum either anteriorly, posteriorly or both). The posterior variant is essentially posterosuperior instability and the pathology can be considered the equivalent of the anteroinferior Bankart lesion.

Labral injuries are common in overhead athletes as a progressive failure of the labrum, or may occur as a traumatic event in association with anterior dislocation.[29,80]

Diagnosis

There are no clinical tests that are both valid and reliable for the diagnosis of labral tears. Diagnosis is by clinical suspicion and confirmed by MR arthrography.

Typically, there is a predominance of athletic males in their early to mid-twenties, who may report activity-related sudden pains in the shoulder, or inability to perform an overhead throw due to pain, in the absence of injury.[81]

The term 'dead arm' is commonly used to describe symptoms, which include a sudden sharp paralysing pain or sense of subluxation associated with weakness, numbness and tingling.82

Others may be unaware of any sense of instability of the shoulder and report vague symptoms of impingement associated with activity, or a particular aspect of an activity, or shoulder fatigue, weakness or loss of endurance.[81,83]

Clicking and locking may also be a feature of instability.[84] In SLAP lesions, pain is usually felt in the anterior shoulder which increases with overhead activities and may also be associated with a painful catching or popping sensation.[85]

Management

Orthopaedic referral is required.

Acromioclavicular joint disorders

Overview

- AC joint injury mostly occurs as a result of a fall on the point of the shoulder, and presents as localised AC joint tenderness and limited movement due to pain.
- Radiology is only useful for assessing the degree of damage, as management is determined by the severity of the injury.
  - Mild injuries are best managed non-operatively.
  - Moderate injuries are usually managed non-operatively for 3 months before surgery is considered.
  - Severe injuries are usually best managed surgically.
- Distal clavicular osteolysis may occur with trauma or repetitive activity, and presents with dull AC joint pain and tenderness, inability to lie on the affected side at night, and painful adduction. Activity modification is usually helpful, but specialist referral is appropriate where this is not an option or not successful.

Good practice points	
✓	Imaging • If surgery is an option for an AC joint dislocation, perform x-rays to stage the degree of dislocation.
✓	Management • People with Grade I and II sprains can be provided with a sling and analgesics for 5 – 7 days until comfortable. • Advise gradual return to activity as symptoms settle, and avoidance of heavy lifting and contact sports for 8 – 12 weeks. • People with Grade III AC joint sprains can also be managed non-operatively but if this is not successful after 3 months, consider referral to a specialist for further evaluation. • More serious AC joint dislocations require referral for orthopaedic evaluation.
Recommended practice based on the professional experience of the Guideline Development Team where there is no other evidence available	

Background

AC joint injuries are more common in men and typically occur between the second and fourth decades of life, from a fall on the point of the shoulder (eg, rugby, skiing, cycling).[86]

AC joint injuries are classified according to the extent of the damage.[86,87]

- Grade I: Intact joint with minor tear of the AC ligaments.
- Grade II: Up to 50% vertical subluxation of the clavicle with rupture of the AC ligament and stretching of the coracoclavicular ligaments.
- Grade III: >50% vertical subluxation of the clavicle with complete rupture of both AC and coracoclavicular ligaments.

Diagnosis

Local tenderness on palpation of the AC joint and limited range of motion secondary to pain are indicative of involvement of the AC joint.[88]

Asymmetry of the contours of the painful shoulder compared with the unaffected shoulder alerts the clinician to the presence of Grade II or greater AC joint injury. However, deformity may only become apparent after several weeks when pain and muscle spasm diminish, allowing the weight of the arm to sublux the AC joint.

The cross-arm horizontal adduction test and the active compression test (O'Brien's test) have been described for diagnosis of AC joint pathology, but there is no evidence that either test is both reliable and valid.[89]

Imaging

Rockwood states that 'plain radiography continues to be the most readily available, cost-effective method for routine investigation of injuries to the AC joint'.[86]

Weighted views have been recommended for the diagnosis of occult Grade III AC joint dislocations, although there is weak evidence to suggest that they are not effective.87[D+]

A recent survey of 112 practicing members of the American Shoulder and Elbow Surgeons in the USA and Canada found that 57% did not use weighted views, and of those that did (43%), the results were not used to determine surgical intervention.[90]

Management

Grade I & II

Most people with a Grade I or II AC joint sprains will recover full painless function with non-operative management. Various methods of taping are used in the early management of these injuries but there is a lack of evidence to support this. These injuries are generally treated with a sling for 5 – 7 days until the person is comfortable.[91][4] Ice and analgesics may provide some initial pain relief, while gentle mobilisation and strengthening can be initiated when symptoms settle.91[4] Return to usual activity can be expected within 2 – 3 weeks.[91][4] Heavy lifting and contact sports should be avoided for 8 – 12 weeks.[86][4]

Grade III

There is controversy about the management of Grade III AC joint dislocations. There is insufficient evidence to recommend either non-operative or operative management, but there is general agreement in the literature that non-operative management of these injuries is appropriate.[92][1+] [86][4] Manage these injuries as for Grade I and II sprains. If a trial of non-operative management is not successful after 3 months, consider referral to a specialist for further evaluation.[4] Some subgroups may benefit from surgical stabilisation (eg, athletes involved in overhead sports and people involved in heavy manual labour). If there is any doubt, early referral to an orthopaedic specialist is appropriate.

Serious dislocations (>Grade III)

There is general agreement that in most cases, people with more serious AC joint dislocation should be managed surgically. Refer for specialist evaluation.

Distal clavicular osteolysis

Clavicular osteolysis refers to the resorption of bone from the distal end of the clavicle. This may occur in response to an acute injury (traumatic osteolysis) or in response to repetitive stress on the shoulder, as in weight lifting (atraumatic osteolysis).[86]

Clinical features include a dull ache over the AC joint and inability to lie on the affected side at night. As it becomes more severe, activities of daily living may become more painful. Physical examination reveals tenderness over the AC joint which is more marked on horizontal adduction. Range of movement may be full, but associated with impingement signs.[93]

Radiographic features include apparent widening of the joint space, and distal clavicular erosion.[94]

Most people with distal clavicular osteolysis will respond to non-operative management, the most important component being activity modification. People who do not respond to non-operative management, or who are unable to modify their activities, need a referral for specialist evaluation.[93]

Sternoclavicular joint disorders

Overview

- Injuries to the SC joint are uncommon, occurring mainly as a result of compression forces to the chest in motor vehicle accidents and sport (falls, crush injuries, heavy lifting).
- Local SC joint pain and tenderness occur, with a variable gap in the SC joint depending on the degree of damage.
- Mild and moderate sprains can be managed non-operatively.
- Severe sprains (dislocations) require specialist evaluation.
  - Posterior dislocation may damage major blood vessels, trachea and/or oesophagus, causing pulmonary and/or vascular compromise.

Good practice points	
✓	Although rare, clinicians should watch for pulmonary or vascular compromise due to a posterior dislocation of the SC joint usually resulting from severe compression trauma. Immediate referral to an appropriate specialist is indicated.
✓	Most injuries of the SC joint are mild sprains and can be managed with a sling, analgesics and return to activity as tolerated.
Recommended practice based on the professional experience of the Guideline Development Team where there is no other evidence available	

Background

SC joint disorders can be traumatic (involving sprains and dislocations), or atraumatic, the latter not being common and outside the scope of this guideline.

SC dislocations are rare. The most common causes of injury is a motor vehicle accident, followed by sporting injuries.[95] Falls, crush injuries and heavy lifting have also been reported as causes of SC joint injuries.[96]

Sprains of the SC joint are described as mild, moderate or severe. In a mild sprain, the ligaments are intact and the joint is stable. In a moderate sprain, the joint is subluxed and ligaments may be partially disrupted. A severe sprain involves dislocation of the joint.[95]

Anterior dislocations are more common than posterior dislocations. In the latter, it is important to remember the proximity of the major vessels, trachea and oesophagus.[97]

Diagnosis

An SC joint injury should be suspected with any history of a direct blow to the anterior chest or indirect trauma to the shoulder girdle resulting in tenderness over the SC joint.[96]

A mild sprain of the SC joint is the most common injury and is characterised by local tenderness and swelling with no evidence of instability.

In a more severe injury, pain is typically severe and localised, with the arm held across the chest. A palpable gap in the joint may be present.

People with a complete dislocation may exhibit signs of pulmonary or vascular compromise.[98] Breathing difficulties, shortness of breath, or a feeling of suffocation or hoarseness should alert the clinician to the possibility of tracheal compression. Oesophageal compression may manifest as a difficulty in swallowing or a tight feeling in the throat.[96]

Vascular compromise in the upper limb is suggestive of an injury to the inominate artery, or the subclavian artery or vein.[96] Any evidence of compromise of the airway or blood supply requires immediate referral to a specialist.

Observation for deformity and direct palpation for tenderness and swelling are the most usual ways of determining an SC joint injury.[96]

Imaging

Routine x-rays of the SC joint are difficult to interpret. Various views have been suggested, but none are ideal. CT may be the best radiological technique for the diagnosis of SC joint pathologies.[95-97][4]

Management

Acute sprains of the SC joint may benefit from local application of ice and a sling for a few days with early active movement as tolerated.[95][4] Mild sprains resolve within 7 – 10 days, while a moderate sprain may take 3 – 6 weeks.[96][4] Management is difficult, as once the disc is damaged, there is a high likelihood of pain and subsequent arthritis.

People with complete dislocations of the joint associated with significant trauma should be referred for specialist evaluation and treatment. Pulmonary or vascular complications require immediate referral.[95][4]

Cultural considerations

An increasing cultural diversity in New Zealand provides an opportunity for health practitioners to embrace other cultures so that health gains are not compromised.99 The Treaty of Waitangi provides for a special relationship between Maori and the Crown in all aspects of health care, based on the three principles of partnership, participation and protection.

Health care practitioners should be aware that people from different cultures may have different belief systems that sometimes means they view the health system and its treatments differently from those with scientifically-based practices. Recognition and respect for other knowledge systems is central to the concept of cultural competence and practitioners should look for opportunities for collaboration which include both approaches.99

Maori

Maori are more likely than non-Maori to be injured at work. This reflects the types of occupations in which Maori are more likely to be involved, such as manual and trade occupations. A high involvement in sport is another reason for higher injury rates in Maori adults. Nearly half (47%) of Maori aged 15 – 24 years and 31% of Maori aged 25 – 44 years reported being injured in a sport/game setting in the New Zealand Health Survey 1996/97.100 While there are no specific data, it is likely that a significant proportion of these injuries are shoulder injuries that require management at the primary care level. Access to appropriate care is a concern. It has been documented that Maori receive less care than non-Maori for ankle injuries and there is no reason to believe this would be different for shoulder injuries.101 Further research is required to verify this and to identify other specific issues relating to access to appropriate care for Maori with a shoulder injury.

Pacific peoples

An understanding of Pacific peoples' diversity and culture and the way in which this can influence a Pacific person's viewpoint on health is necessary. Such an understanding will help the health practitioner gain the Pacific person's confidence and facilitate the history taking, physical examination, diagnosis and management of soft tissue injuries of the shoulder resulting in better outcomes.

Problems of access to primary care for Pacific peoples have been well documented.102 Pacific peoples may benefit from resources to help with transport to and from the primary and secondary health care providers, or from resources to enable them to be managed within the community.

For both Maori and Pacific peoples with a shoulder injury, commonsense, courtesy and respect go a long way to cross cultural barriers that may exist. Most cultural differences can be overcome if treatment options are explained thoroughly in a language that is understood. Providing educational material in the person's own language may also improve the quality of care for Maori and Pacific peoples.

Recommendation	
C	Health care practitioners providing care for M ori and Pacific peoples should be sensitive to their particular needs.
Grades indicate the strength of supporting evidence, rather than the importance of the recommendations – refer to page 49 for grading details.	

Implementation

Two initial strategies will be undertaken to disseminate and implement the guideline.

1. The completed guideline and supporting material will be posted on the NZGG and ACC websites.

2. A laminated summary version of the guideline will be circulated to all groups involved in the diagnosis and management of soft tissue shoulder injuries. It will contain:

    i. key messages

    ii. diagnostic and management flowchart

    iii. a basic shoulder examination.

The Guideline Development Team suggests that ACC, NZGG and other relevant parties develop a detailed implementation plan.

Further research

Research topics that would improve the management of shoulder injuries in primary care have been identified below.

- Evaluation of the effectiveness of the algorithm in improving diagnosis and management of shoulder injuries in the primary care setting.
- Development and validation of clinical decision rules for the use of diagnostic ultrasound and radiography for shoulder injuries.
- Evaluation of the appropriateness of referrals to the various specialist groups and development and validation of referral guidelines.
- Development and validation of indicators to improve the quality of care for musculoskeletal injuries in primary care.
- Performance of a randomised trial to investigate the effectiveness of primary surgical repair in young physically active people with a first acute traumatic dislocation.
- Performance of randomised trials to investigate the effectiveness of various rehabilitation interventions for people with rotator cuff disorders, frozen shoulder and instability.

Appendices

A. Evidence and recommendation grading system

B. Guideline methodology

Appendix A: Evidence and recommendation grading system

For this guideline, grading has only been applied to studies involving diagnostic procedures or therapy interventions. References used for the background text have not been graded, but provide some context for the recommendations.

Quality

The quality of each study was assessed using the Generic Appraisal Tool for Epidemiology (GATE) tools.

http://www.health.auckland.ac.nz/population-health/epidemiology-biostats/epiq/index.html).

Each study was graded according to the following criteria:

+	Good: Very low risk of bias; met all criteria
~	Fair: Low risk of bias
x	Poor: Risk of bias; most criteria not met

Levels of evidence for therapy

The Guideline Development Team ranked the evidence according to the revised system of the Scottish Intercollegiate Guidelines Network (SIGN). Evidence statements relating to interventions have been assigned a grading according to the 'strength' of the supporting evidence where 1 is the best quality evidence and 4 is expert opinion.

Adapted SIGN Grading System used to identify level of evidence	
1++	High quality meta-analyses, systematic reviews of RCTs, or RCTs with a very low risk of bias
1+	Well conducted meta-analysis, systematic reviews of RCTs or RCTs with a low risk of bias
1-	Well conducted meta-analysis, systematic reviews of RCTs or RCTs with a high risk of bias
2++	High quality systematic reviews of case-control or cohort studies High quality case-control or cohort studies with a very low risk of confounding, bias, or chance and a high probability that the relationship is causal
2+	Well conducted case control or cohort studies with a low risk of confounding, bias, or chance and a moderate probability that the relationship is causal
2 -	Case control or cohort studies with a high risk of confounding, bias, or chance and a significant risk that the relationship is not causal
3	Non-analytic studies, eg, case reports, case series
4	Expert Opinion eg, narrative reviews, expert panel

Note: Level of evidence [4] in this guideline includes both published expert opinion and the consensus of the Guideline Development Team.

Levels of evidence for diagnostic tests

Inclusion criteria

The key criteria used to evaluate the quality of diagnostic test studies were:

- number of participants >35
- blind independent assessment of the new test and the reference standard
- comparison of a reference test with the new test in >90% of people
- an appropriate spectrum of people or a defined clinical group.

Only studies with a level of evidence D++ or D+ were included in this guideline.

Levels of evidence

Single diagnostic studies	
D++	Good: All four criteria met
D+	Fair: One or two of the criteria not met
D-	Poor: None of the criteria met.

Diagnostic Systematic Reviews	
DSR++	High quality meta-analysis or systematic review of diagnostic studies
DSR+	Fair quality meta-analysis or systematic review of diagnostic studies
DSR-	Poor quality meta-analysis or systematic review of diagnostic studies.

Grading

The final step in grading is to consider the WHOLE BODY OF EVIDENCE ie, all the studies relevant to the issue, and decide on a recommendation using a considered judgment process.

Grades of recommendation	
A	The recommendation is supported by good evidence
B	The recommendation is supported by fair evidence
C	The recommendation is supported by expert opinion only eg, published consensus document
I	No recommendation can be made because the evidence is insufficient ie, evidence is lacking, of poor quality or conflicting and the balance of benefits and harms cannot be determined.

Good practice points	
✓	Recommended practice based on the professional experience of the Guideline Development Team where there is no other evidence

The grades are not listed in hierarchical order. Instead, the most important recommendation will be listed first and so on.

Target group

The target group for the guideline is primary care practitioners. This group includes primary care medical practitioners, physiotherapists and osteopaths who are able to assess soft tissue injuries of the shoulder and decide initial management.

Consumers are also an important target group. A focus group meeting was held to gain a more in-depth understanding from the consumer perspective of issues in the diagnosis and management of shoulder injuries. Consumers were also consulted during the development of the Consumer Information Brochure.

Scope of the guideline

Inclusions

This guideline addresses the diagnosis and management of people with the following shoulder injuries:

- rotator cuff disorders
- frozen shoulder
- GH instabilities (acute and recurrent dislocation, other instabilities)
- AC and SC injuries.

Exclusions

- Fractures
- Inflammatory conditions
- Degenerative conditions
- Endocrinological and neurological conditions
- Hemiplegic shoulder
- Chronic shoulder pain including occupational overuse disorders

Note: There is currently insufficient information to consider the risks and benefits of diagnostic procedures and treatment interventions to complete a balance sheet for shoulder injuries.

Criteria used to locate and include studies

Types of Studies

- Systematic reviews, meta-analyses and randomised trials were included
- Only published studies in the English language were considered for inclusion

Participants

- Adults with injuries of the shoulder and related disorders
- Adolescents for instabilities only, given that dislocation and recurrent dislocation are more common

Types of interventions

Diagnosis

- Clinical tests
- Radiography
- Diagnostic ultrasound
- MRI

Treatment

- Medication (simple analgesics, NSAIDs)
- Corticosteroid injection
- Physiotherapy interventions (electrotherapy, exercise therapy)
- Acupuncture

Search strategy

Comprehensive searching was undertaken:

- General databases: Medline, CINAHL, EMBASE, AMED, SPORTDiscus, Current Contents
- Cochrane Library [Systematic Reviews, Controlled Trials Register, Database of Abstracts of Reviews of Effectiveness (DARE)]

Selected internet sites

- PEDRo (Physiotherapy Evidence Database) www.ptwww.chs.usyd.edu.as/pedro/
- NHS Clinical Trials
- Health Technology Assessment for NHS www.hta.nhsweb.nhs.uk/
- NHS Centre for Reviews and Dissemination www.york.ac.uk/inst/crd/listong.htm
- New Zealand Health Technology Assessment www.nzhta.chmeds.ac.nz
- Bandolier www.jr2.ox.ac.uk/bandolier/
- National Guideline Clearing House www.guideline.gov/index/asp
- American Association of Orthopaedic specialists (AAOS) http://www.aaos.org/

Reference lists of included studies and relevant reviews were checked for further trials.

Key words used in the search strategy are listed in the evidence document (available from the NZGG website www.nzgg.org.nz) which also contains evidence tables for the included studies.

Abbreviations

ACC	Accident Compensation Corporation
AC	Acromioclavicular
CT	Computed Tomography Imaging
EPIQ	Effective Practice, Informatics & Quality Improvement
ESWT	Extracorporeal shock wave therapy
GH	Glenohumeral
IAL	Intra-articular lidocaine
IV	Intra-venous
MRI	Magnetic Resonance Imaging
NSAID	Non-steroidal anti-inflammatory drug
ROM	Range of movement
NZGG	New Zealand Guidelines Group
SLAP	Superior labrum anterior to posterior
SC	Sternoclavicular

Glossary

Amyotrophy: See Neuralgic amyotrophy

Arthrography: An x-ray technique in which a dye is injected into a joint allowing better visualisation of damage to the structures of the joint.

Collageneogenesis: Regeneration of collagen tissue.

Complex Regional Pain Syndrome:
(CRPS) Used to be described as reflex sympathetic dystrophy. It is a chronic pain condition believed to be due to the result of dysfunction in the central or peripheral nervous system, characterised by severe pain, changes in the colour and temperature of the skin, sweating and swelling. It can be triggered by tissue injury or nerve injury.

Disability: A limitation in performance of socially defined roles and tasks within a sociocultural and physical environment (eg, inability to perform in sport).

Dystrophic calcification:
Calcification occurring in degenerated or necrotic tissue.

Electrotherapy: Electrophysical modalities used for therapeutic purposes by physiotherapists.

Extracorporeal Shock Wave Therapy (ESWT):
Focused sonic shock waves delivered to the body to break up calcium deposits in the shoulder. Also used for renal and gallstones.

Glenoid fossa: The 'socket' part of the shoulder joint.

Hemiplegic shoulder:
a person who has had a stroke and is paralysed on one side of the body often suffers from a painful shoulder due to a lack of muscle control to protect the shoulder.

Hydrodilation: A technique used to stretch the capsule in a frozen shoulder by distending it with fluid.

Impairment: The loss of, or abnormality in anatomic or physiologic structure or function at the level of an organ (eg, loss of range of movement or strength).

Instability: A sense of instability or dislocation of the shoulder experienced by the person usually during activity.

Laser: A concentrated light beam of the electromagnetic spectrum between 630 and 1300 nm, used for the treatment of pain in musculoskeletal injuries. The physiological effects are unclear.

Laxity: An excess range of movement in the shoulder joint not associated with symptoms.

Labrum: The labrum is a rim of soft fibrous tissue that deepens the shoulder socket particularly in the inferior half.

Myofascial pain: A group of muscle disorders characterised by the presence of hypersensitive points, called trigger points associated with pain, muscle spasm, tenderness, stiffness, limitation of motion, weakness, and occasionally autonomic dysfunction.

Neuralgic amyotrophy: This condition, also known as Parsonage Turners Syndrome or brachial neuritis, is characterised by severe pain lasting about 2 weeks followed by motor weakness with or without sensory loss.

Polymyalgia rheumatica: An inflammatory disorder causing pain and stiffness in the neck and shoulder area, typically affecting people in their 60s and 70s.

Osteophyte: An outgrowth of bone usually associated with joint degeneration.

Os Acromionale: An ossification centre occurring at the end of the acromion which may resemble a fracture of the acromion. It may be associated with pain due to impingement of the rotator cuff.

Red flags: Signs and symptoms which alert the clinician that more serious pathology may exist, and usually require prompt attention.

Rehabilitation: A process that involves any procedure designed to maximise function after injury or illness.

Rotator cuff: The rotator cuff is a group of four muscles providing stability at the shoulder joint. It includes subscapularis, supraspinatus, infraspinatus and teres minor.

Scapulothoracic articulation: The area where the scapula, which is embedded in muscle, glides over the rib cage.

Subacromial: A space in the shoulder joint beneath the acromion.

Subluxation: Partial dislocation.

Zygoapophyseal joint: A spinal facet joint.

References

1. van der Heijden GJ. Shoulder disorders: state of the art review. *Baillieres Clinical Rheumatology* 1999; 13:287-309.

2. Stevenson JH, Trojian T. Evaluation of shoulder pain. *Journal of Family Practice* 2002; 51(7):605-11.

3. Zhang Z, Bennett S, Wang J, Byrne K, Mallett S. The general description of shoulder injuries using routinely collected ACC data. Wellington: Accident Compensation Corporation, 2003.

4. Stiles RG, Otte MT. Imaging of the shoulder. *Radiology* 1993; 188:603-613.

5. Dinnes J, Loveman E, McIntyre LF, Waugh N. The effectiveness of diagnostic tests for the assessment of shoulder pain due to soft tissue disorders: a systematic review. *Health Technology Assessment* 2003; 7(29).

6. Singh RB, Hunter JC, Smith KL. MRI of shoulder instability: state of the art. *Current Problems in Diagnostic Radiology* 2003; 32(3):127-134.

7. Palmer WE, Brown JH, Rosenthal DI. Labral-ligamentous complex of the shoulder: Evaluation with MR arthrography. *Radiology* 1994; 190(3):645-651.

8. Palmer WE, Caslowitz PL. Anterior shoulder instability: diagnostic criteria determined from prospective analysis of 121 MR arthrograms. *Radiology* 1995; 197(3):819-25.

9. Willemsen UF, Wiedemann E, Brunner U, Scheck R, Pfluger T, Kueffer G, et al. Prospective evaluation of MR arthrography performed with high-volume intraarticular saline enhancement in patients with recurrent anterior dislocations of the shoulder. *American Journal of Roentgenology* 1998; 170(1):79-84.

10. Bencardino JT, Beltran J, Rosenberg ZS, Rokito A, Schmahmann S, Mota J, *et al*. Superior labrum anterior-posterior lesions: diagnosis with MR arthrography of the shoulder. *Radiology* 2000; 214(1):267-71.

11. Sher JS. Anatomy, biomechanics and pathophysiology of rotator cuff disease. In: Iannotti JP, Williams GR, Jr., editors. *Disorders of the Shoulder: Diagnosis and Management*. Philadelphia: Lippincott, Williams & Wilkins, 1999.

12. Ejnisman B, Carrera EF, Fallopa F, Peccin MS, Cohen M. Interventions for tears of the rotator cuff in adults. *Cochrane Library* 2004 (Issue 1).

13. Matsen FA, Arntz CT, Lippitt S. Rotator Cuff. In: Rockwood CA, Matsen FA, editors. *The Shoulder*. 2nd ed. Philadelphia: W.B. Saunders, 1998.

14. Khan KM, Cook JL, Taunton JE, Bonar F. Overuse tendinosis: not tendinitis. Part 1: a new paradigm for a difficult clinical problem. *Physician & Sportsmedicine* 2000; 28(5):31-46.

15. Fukuda H. The management of partial-thickness tears of the rotator cuff. *Journal of Bone and Joint Surgery - Series B* 2003; 85(1):3-11.

16. Gerber C. Massive rotator cuff tears. In: Iannotti JP, Williams GR, Jr., editors. Disorders of the Shoulder: Diagnosis and Management. Philadelphia: Lippincott, Williams and Wilkins, 1999.

17. Arroyo JS, Flatow EL. Management of rotator cuff disease: intact and repairable cuff. In: Iannotti JP, Williams GR, Jr., editors. Disorders of the Shoulder: Diagnosis and Management. Philadelphia: Lippincott, Williams and Wilkins, 1999.

18. Tytherleigh-Strong G, Hirahara A, Miniaci A. Rotator cuff disease. *Current Opinion in Rheumatology* 2001; 13(2):135-145.

19. Tennent TD, Beach WR, Meyers JF. A review of the special tests associated with shoulder examination; part I: the rotator cuff tests. *American Journal of Sports Medicine* 2003; 31(1):154-160.

20. Green A. Physiotherapy interventions for shoulder pain. *Cochrane Database of Systematic Reviews* 2003(3).

21. Green S, Buchbinder R, Glazier R, Forbes A. Interventions for shoulder pain. *Cochrane Library* 2004(Issue 1).

22. van der Windt DA, van der Heijden GJ, Scholten RJ, Koes BW, Bouter LM. The efficacy of non-steroidal anti-inflammatory drugs (NSAIDS) for shoulder complaints. *Journal of Clinical Epidemiology* 1995; 48:691-704.

23. Anonymous. Acute pain management: scientific evidence: National Health and Medical Research Council, 1999.

24. Buchbinder R, Green S, Youd JM. Corticosteroid injections for shoulder pain. *Cochrane Database of Systematic Reviews* 2003(1):CD004016.

25. Arroll B, Goodyear-Smith F. Corticosteroid injections for painful shoulder: a meta-analysis. Wellington: Accident Compensation Corporation, 2003.

26. Hay EM, Thomas E, Paterson SM, Dziedzic K, Croft PR. A pragmatic randomised trial of local corticosteroid injection and physiotherapy for the treatment of new episodes of unilateral shoulder pain in primary care. *Annals of Rheumatic Diseases* 2003; 62:394-399.

27. van der Windt DA, Koes BW, Deville W, Boeke AJ, de Jong BA, Bouter LM. Effectiveness of corticosteroid injections versus physiotherapy for treatment of painful stiff shoulder in primary care: randomised trial. *BMJ* 1998; 317(7168):1292-6.

28. Cardone DA, Tallia AF. Joint and soft tissue injection. *American Family Physician* 2002; 66(2):283-288.

29. Yamaguchi K, Bindra R. Disorders of the biceps tendon. In: Iannotti JP, Williams GR, Jr., editors. *Disorders of the Shoulder: Diagnosis and Management*. Philadelphia: Lippincott, Williams and Wilkins, 1999.

30. Gerdesmeyer L, Wagenpfeil S, Haake M, Maier M, Loew M, Wortler K, et al. Extracorporeal shock wave therapy for the treatment of chronic calcifying tendonitis of the rotator cuff: a randomised controlled trial. *Journal of the American Medical Association* 2003; 290(19):2573-2580.

31. Haake M, Deike B, Thon A, Schmitt J. Exact focusing of extracorporeal shock wave therapy for calcifying tendinopathy. *Clinical Orthopaedics & Related Research* 2002; 397:323-331.

32. Ebenbichler GR, Erdogmus CB, Resch KL, Funovics MA, Kainberger F, Barisani G, et al. Ultrasound therapy for calcific tendinitis of the shoulder [comment]. *New England Journal of Medicine* 1999; 340(20):1533-8.

33. Thiel M. Application of Shock Waves in Medicine. *Clinical Orthopaedics & Related Research* 2001; 387(18-21).

34. Pan P, Chou CL, Chiou HJ, Ma HL, Lee HC, Chan RC. Extracorporeal shock wave therapy for chronic calcific tendinitis of the shoulders: a functional and sonographic study. *Archives of Physical Medicine & Rehabilitation* 2003; 84:988-993.

35. Cosentino R, De Stefano R, Selvi E, Frati E, Manca S, Frediani B, et al. Extracorporeal shock wave therapy for chronic calcific tendinitis of the shoulder: single blind study. *Annals of the Rheumatic Diseases* 2003; 62(3):248-250.

36. Loew M, Daecke W, Kusnierczak D, Rahmanzadeh M, Ewerbeck V. Shock-wave therapy is effective for chronic calcifying tendinitis of the shoulder. *Journal of Bone & Joint Surgery - British Volume* 1999; 81(5):863-7.

37. Warner JJ, Answorth AA. Diagnosis and management of subscpularis tendon tears. *Techniques in Orthopaedics* 1994; 9:116-125.

38. Caughey MA, Welsh P. Muscle ruptures affecting the shoulder girdle. In: Rockwood CA, Matsen FA, editors. *The Shoulder*. 2nd ed. Philadelphia: W.B. Saunders, 1998.

39. Dodds SD, Wolfe SW. Injuries to the pectoralis major. *Sports Medicine* 2002; 32(14):945-52.

40. Harryman DT, Lazarus JM, Rozencwaig R. The stiff shoulder. In: Rockwood CA, Matsen FA, editors. *The Shoulder*. 2nd ed. Philadelphia: W.B. Saunders, 1998.

41. Rizk TE, Pinals RS. Frozen shoulder. *Seminars in Arthritis & Rheumatism* 1982; 11(4):440-452.

42. Noel E, Thomas T, Schaeverbeke T, Thomas P, Bonjean M, Revel M. Frozen shoulder. *Joint, Bone, Spine: Revue du Rhumatisme* 2000; 67(5):393-400.

43. Smith L, Burnet SP, McNeil JD. Musculoskeletal manifestations of diabetes mellitus. *British Journal of Sports Medicine* 2003; 37:30-35.

44. Grubbs N. Frozen shoulder syndrome: a review of literature. *Journal of Orthopaedic & Sports Physical Therapy* 1993; 18(3):479-87.

45. Cuomo F. Disorders of the Shoulder: Diagnosis and Management. In: Iannotti JP, Williams GR, Jr., editors. *Disorders of the Shoulder: Diagnosis and Management*. Philadelphia: Lippincott, Williams & Wilkins, 1999.

46. Neviaser RJ, Neviaser TJ. The frozen shoulder; diagnosis and management. *Clinical Orthopaedics & Related Research Issue* 1987; 223:59-64.

47. Carette S, Moffet H, Tardif J, Bessette L, Morin F, Fremont P, et al. Intra-articular corticosteroids, supervised physiotherapy, or a combination of the two in the treatment of adhesive capsulitis of the shoulder: a placebo-controlled trial. *Arthritis and Rheumatism* 2003; 48(3):829-838.

48. Sun KO, Chan KC, Lo SL, Fong DY. Acupuncture for frozen shoulder. *Hong Kong Medical Journal* 2001; 7(4):381-91.

49. Cole BJ, Warner JJ. Anatomy, biomechanics, and pathophysiology of glenohumeral instability. In: Iannotti JP, Williams GR, Jr., editors. *Disorders of the Shoulder: Diagnosis and Management*. Philadelphia: Lippincott, Williams & Wilkins, 1999.

50. Liu SH, Mark H. Anterior shoulder instability: current review. *Clinical Orthopaedics & Related Research* 1996; 323:327-337.

51. Matsen FA, Thomas SC, Rockwood CA, Wirth CJ. Glenohumeral instability. In: Rockwood CA, Matsen FA, editors. *The Shoulder*. 2nd ed. Philadelphia: W.B. Saunders, 1998.

52. Hayes K, Callanan M, Walton J, Paxinos A, Murrell GA. Shoulder instability: management and rehabilitation. *Journal of Orthopaedic & Sports Physical Therapy* 2002; 32(10):497-509.

53. Beeson MS. Complications of shoulder dislocation. *American Journal of Emergency Medicine* 1999; 17(3):288-95.

54. Perlmutter GS. Axillary nerve injury. *Clinical Orthopaedics & Related Research* 1999; 368:28-36.

55. Perron AD, Ingerski MS, Brady WJ, Erling BF, Ullman EA. Acute complications associated with shoulder dislocation at an academic emergency department. *Journal of Emergency Medicine* 2003; 24(2):141-145.

56. Visser CPJ, Coene NJ, Brand R, Tavy DJ. The incidence of nerve injury in anterior dislocation of the shoulder and its influence on functional recovery. *Journal of Bone & Joint Surgery - British Volume* 1999; 81(4):679-85.

57. Matthews LS, Pavlovich LJ. Anterior and anteroinferior instability: diagnosis and management. In: Iannotti JP, Williams GR, Jr., editors. *Disorders of the Shoulder: Diagnosis and Management*. Philadelphia: Lippincott, Williams & Wilkins, 1999.

58. Hendey GW, Kinlaw K. Clinically significant abnormalities in postreduction radiographs after anterior shoulder dislocation [comment]. *Annals of Emergency Medicine* 1996; 28(4):399-402.

59. Hendey G. Necessity of radiographs in the emergency department management of shoulder disolocations. *Annals of Emergency Medicine* 2000; 36(2):108-113.

60. Shuster M, Abu-Laban RB, Boyd J. Prereduction radiographs in clinically evident anterior shoulder dislocation. *American Journal of Emergency Medicine* 1999; 17(7):653-8.

61. Harvey RA, Trabulsy ME, Roe L. Are post-reduction anteroposterior and scapular Y views useful in anterior shoulder dislocations? *American Journal of Emergency Medicine* 1992; 10:149-151.

62. Beattie TF, Steedman DJ, McGowan A, Robertson CE. A comparison of the Milch and Kocher techniques for acute anterior dislocation of the shoulder. *Injury* 1986; 17(5):349-52.

63. Schubert H. Emergency case: reducing anterior shoulder dislocation. Easy is good. *Canadian Family Physician* 2002; 48:469-472.

64. Orlinsky M, Shon S, Chiang C, Chan L, Carter P. Comparative study of intra-articular lidocaine and intravenous meperidine/diazepam for shoulder dislocations. *Journal of Emergency Medicine* 2002; 22(3):241-245.

65. Matthews DE, Roberts T, McInerney V. Intraarticular lidocaine versus intravenous analgesic for reduction of acute anterior shoulder dislocations. A prospective randomized study. *American Journal of Sports Medicine* 1995; 23(1):54-58.

66. Kosnik J, Shamsa F, Raphael E, Huang R, Malachias Z, Georgiadis GM. Anesthetic methods for reduction of acute shoulder dislocations: a prospective randomized study comparing intraarticular lidocaine with intravenous analgesia and sedation. *American Journal of Emergency Medicine* 1999; 17(6):566-70.

67. Itoi E, Hatakeyama Y, Kido T. A new method of immobilization after traumatic anterior dislocation of the shoulder: a preliminary study. *Journal of Shoulder & Elbow Surgery* 2003; 12(5):413-415.

68. Hawkins RJ, Mohtadi NG. Controversy in anterior shoulder instability. *Clinical Orthopaedics & Related Research* 1991(272):152-61.

69. Handoll HHG, Almaiyah MA, Rangan A. Surgical versus non-surgical treatment for acute anterior shoulder dislocation. *Cochrane Database of Systematic Reviews* 2004 (Issue 1).

70. Jackins S, Matsen FA, 3rd. Management of shoulder instability. *Journal of Hand Therapy* 1994; 7(2):99-106.

71. Kralinger FS, Golser K, Wischatta R, Wambacher M, Sperner G. Predicting recurrence after primary anterior shoulder dislocation. *American Journal of Sports Medicine* 2002; 30(1):116-20.

72. Dines DM, Levinson M. The conservative management of the unstable shoulder including rehabilitation. *Clinics in Sports Medicine* 1995; 14(4):797-816.

73. Itoi E, Hatakeyama Y, Urayama M, Pradhan RL, Kido T, Sato K. Position of immobilization after dislocation of the shoulder: a cadaveric study. *Journal of Bone and Joint Surgery (Series A)* 1999; 81(3):385-390.

74. Should acute anterior dislocation of the shoulder be treated in external rotation? 48th Annual Meeting of the Orthopaedic Research Society; 2002; Dallas, Texas. Available at www.ors.org/Transactions/48/0830.pdf [Accessed January 2004].

75. Murrell GA. Treatment of shoulder dislocation: is a sling appropriate? *Medical Journal of Australia* 2003; 179:370-371.

76. Ramsey ML, Klimkiewicz JJ. Posterior instability: diagnosis and management. In: Iannotti JP, Williams GR, Jr., editors. *Disorders of the Shoulder: Diagnosis and Management*. Philadelphia: Lippincott, Williams & Wilkins, 1999.

77. Pollock RG, Biglani LU. Recurrent posterior shoulder instability. *Clinical Orthopaedics & Related Research* 1993; 291:85-96.

78. Schenk TJ, Brems JJ. Multidirectional instability of the shoulder: pathophysiology, diagnosis, and management. *Journal of the American Academy of Orthopaedic Surgeons* 1998; 6(1):65-72.

79. An YH, Friedman RJ. Multidirectional instability of the glenohumeral joint. *Orthopedic Clinics of North America* 2000; 31(2):275-85.

80. Parentis MA, Mohr KJ, El Attrache NS. Disorders of the superior labrum: review and treatment guidelines. *Clinical Orthopaedics & Related Research* 2002(400):77-87.

81. Kvitne RS, Jobe FW. The diagnosis and treatment of anterior instability in the throwing athlete. *Clinical Orthopaedics & Related Research* 1993(291):107-23.

82. Rowe CR. Recurrent transient anterior subluxation of the shoulder. *Clinical Orthopaedics & Related Research* 1987; 223:11-19.

83. Rames RD, Karzel RP. Injuries to the glenoid labrum, including SLAP lesions. *Orthopedic Clinics of North America* 1993; 24(1):45-53.

84. Magarey M, Jones MA, Grant ER. Biomedical considerations and clinical patterns related to disorders of the glenoid labrum in the predominantly stable glenohumeral joint. *Manual Therapy* 1996; 1(5):242-249.

85. Snyder SJ, Karzel RP, Del Pizzo W. SLAP lesions of the shoulder. *Arthroscopy* 1990; 6:274-279.

86. Rockwood CA, Williams GR, Young DC. Disorders of the acromioclavicular joint. In: Rockwood CA, Matsen FA, editors. *The Shoulder*. 2nd ed. Philadelphia: W.B. Saunders, 1998.

87. Bossart PJ, Jouce SM, Manaster BJ, Packer SM. Lack of efficacy of "weighted" radiographs in diagnosing acute acromioclavicular separation. *Annals of Emergency Medicine* 1988; 17(1):20-24.

88. Harris TG, Lynch SA. Acromioclavicular joint separations: update, diagnosis, classification and treatment. *Current Opinion in Orthopedics* 2003; 14:255-261.

89. O'Brien SJ, Pagnani MJ, Fealy S, McGlynn SR, Wilson JB. The active compression test: a new and effective test for diagnosing labral tears and acromioclavicular joint abnormality. *American Journal of Sports Medicine* 1998; 26(5):610-3.

90. Yap JL, Curl LA, Kvitne RS, McFarland EG. The value of weighted views of the acromioclavicular joint. *American Journal of Sports Medicine* 1999; 27(6):806-809.

91. Beim GM. Acromioclavicular joint injuries. *Journal of Athletic Training* 2000; 35(3):261-267.

92. Larsen E, Bjerg-Nielsen A, Christensen P. Conservative or surgical treatment of acromioclavicular dislocation. A prospective, controlled, randomized study. *Journal of Bone & Joint Surgery - American Volume* 1986; 68(4):552-5.

93. Stephens M, Wolin PM, Tarbet JA, Alkhayarin M. Osteolysis of the distal clavicle:readily detected and treated shoulder pain. *Physician & Sportsmedicine* 2000; 28(12):35-6, 39, 43-4.

94. Shaffer BS. Painful conditions of the acromioclavicular joint. *Journal of the American Academy of Orthopaedic Surgeons* 1999; 7(3):176-88.

95. Wirth MA, Rockwood CA. Disorders of the sternoclavicular joint: pathophysiology, diagnosis and management. In: Iannotti JP, Williams GR, Jr., editors. *Disorders of the Shoulder: Diagnosis and Management*. Philadelphia: Lippincott, Williams and Wilkins, 1999.

96. Yeh GL, Williams GR, Jr. Conservative management of sternoclavicular injuries. *Orthopedic Clinics of North America* 2000; 31(2):189-203.

97. Rockwood CA, Wirth MA. Disorders of the sternoclavicular joint. In: Rockwood CA, Matsen FA, editors. *The Shoulder*. 2nd ed. Philadelphia: W.B. Saunders, 1999.

98. Szalay EA, Rockwood CA, Jr. Injuries of the shoulder and arm. *Emergency Medicine Clinics of North America* 1984; 2(2):279-94.

99. Durie M. Cultural Competence and Medical Practice in New Zealand. Wellington, 2001.

100. Te Puni Kokiri. Ministry of Maori Development. Tikanga Oranga Hauora. *Whakapakari* 2000(4).

101. Broad J, Robb G, Ameratunga S, Larmer P, Jackson R. Managing acute soft tissue injuries of the ankle. ACC report: University of Auckland, 2001.

102. Barnett R. Household and vocational variations in the survival strategies of the urban poor. *Health and Place* 2001; 7:141-157.

Printed July 2004 • (Print) ISBN 0478–27916–7 • ACC1617